JOURNAL OF THE AMERICAN COLLEGE OF CARDIOLOGY VOL. 72, NO. 20, 2018
© 2018 BY THE AMERICAN COLLEGE OF CARDIOLOGY FOUNDATION
PUBLISHED BY ELSEVIER

THE PRESENT AND FUTURE

JACC STATE-OF-THE-ART REVIEW

Cardiac Phenotypes in Hereditary Muscle Disorders

JACC State-of-the-Art Review

Eloisa Arbustini, MD,[a] Alessandro Di Toro, MD,[a] Lorenzo Giuliani, MS,[a] Valentina Favalli, PhD,[b] Nupoor Narula, MD,[a,c] Maurizia Grasso, PhD[a]

ABSTRACT

Hereditary muscular diseases commonly involve the heart. Cardiac manifestations encompass a spectrum of phenotypes, including both cardiomyopathies and rhythm disorders. Common biomarkers suggesting cardiomuscular diseases include increased circulating creatine kinase and/or lactic acid levels or disease-specific metabolic indicators. Cardiac and extracardiac traits, imaging tests, family studies, and genetic testing provide precise diagnoses. Cardiac phenotypes are mainly dilated and hypokinetic in dystrophinopathies, Emery-Dreifuss muscular dystrophies, and limb girdle muscular dystrophies; hypertrophic in Friedreich ataxia, mitochondrial diseases, glycogen storage diseases, and fatty acid oxidation disorders; and restrictive in myofibrillar myopathies. Left ventricular noncompaction is variably associated with the different myopathies. Conduction defects and arrhythmias constitute a major phenotype in myotonic dystrophies and skeletal muscle channelopathies. Although the actual cardiac management is rarely based on the cause, the cardiac phenotypes need precise characterization because they are often the only or the predominant manifestations and the prognostic determinants of many hereditary muscle disorders. (J Am Coll Cardiol 2018;72:2485–506)
© 2018 by the American College of Cardiology Foundation.

Hereditary muscle diseases include a heterogeneous spectrum of clinical disorders and causes that comprise dystrophic and nondystrophic myopathies, mitochondrial myopathies, storage myopathies, and muscle channelopathies (1,2). The heart is involved in many of these diseases in which the cardiac phenotype variably includes almost all kinds of cardiomyopathies, conduction defects with or without cardiomyopathies, and supraventricular and ventricular tachyarrhythmias (3,4). The onset of clinical manifestations can occur in the pediatric as well as adult populations (5). As such, both pediatric and adult cardiologists must remain involved in multidisciplinary programs to ensure continuity of care to patients and families (6,7).

The prevalence of precisely diagnosed cardiac manifestations in the different muscle disorders reflects the accuracy of describing the myocardial phenotype. Similarly, the prevalence of different myopathies in patients presenting with heart disease, either cardiomyopathy or rhythm disturbances, reflects the accuracy of the description of the skeletal muscle disease. Precise phenotype and genotype specifications, as proposed by the MOGES (where M is morphofunctional characteristics, O is organ involvement, G is genetic or familial inheritance pattern, E is etiological information, and S is functional status) nosology for cardiomyopathies (8) is essential to classify patients by homogeneous subgroups, thereby allowing for assessment of disease-specific epidemiologic burden. These data would be

Listen to this manuscript's audio summary by *JACC* Editor-in-Chief Dr. Valentin Fuster.

From the [a]Centre for Inherited Cardiovascular Diseases, IRCCS Foundation, University Hospital Policlinico San Matteo, Pavia, Italy; [b]InGenomics, srls, Pavia Technopole, Italy; and the [c]Division of Cardiology, Department of Medicine, New York Presbyterian Hospital, Weill Cornell Medicine, New York, New York. Contents of this paper are from continuous medical research of cardiomyopathies supported by the European Union-funded project INHERITANCE (241924); the Italian Ministry of Health (R.C. Hypertrophic Cardiomyopathy); the Cariplo Foundation; and the Magica Onlus Charity. All other authors have reported that they have no relationships relevant to the contents of this paper to disclose.

Manuscript received May 10, 2018; revised manuscript received July 20, 2018, accepted August 10, 2018.

ISSN 0735-1097/$36.00 https://doi.org/10.1016/j.jacc.2018.08.2182

ABBREVIATIONS AND ACRONYMS

AVB = atrioventricular block

CMR = cardiac magnetic resonance

DCM = dilated cardiomyopathy

HCM = hypertrophic cardiomyopathy

HF = heart failure

LVNC = left ventricular noncompaction

PM = pacemaker

RCM = restrictive cardiomyopathy

sCK = serum creatine kinase

XLR = X-linked recessive

valuable in accelerating the development of targeted treatments for these complex genetic diseases.

Cardiologists are either the first clinicians who might have recognized a heritable cardiac disease that is allelic at the same locus of a muscle disease, or they could be specialist members of multidisciplinary teams who manage cardiomuscular diseases (9). Cardiac phenotypes are useful clinical markers that guide diagnostic suspicion of a specific cause but may also be the first or major clinical manifestation that brings patients to medical attention and affects disease evolution and prognosis. The classification of muscle disorders is complex and based on phenotype, cause, and pathology characteristics (1). This review describes the cardiomyopathic and arrhythmogenic phenotypes in patients with different types of hereditary muscle diseases with cardiac involvement.

DILATED AND HYPOKINETIC PHENOTYPES

The most common heritable muscle diseases with dilated and hypokinetic cardiac phenotypes include the dystrophinopathies, limb girdle muscular dystrophies (LGMD) and Emery-Dreifuss muscular dystrophies (EDMD). In each subgroup, the clinical onset can be either early or late, and the evolution can progress slowly or rapidly. The precise phenotypic and causative diagnosis influences monitoring, risk stratification, and treatments and is essential for ensuring optimal care.

DYSTROPHINOPATHIES. Dilated cardiomyopathy (DCM) is a unique and often fatal cardiac phenotype in patients with dystrophinopathies. These rare X-linked recessive (XLR) muscle diseases are caused by mutations in the *DMD* gene, which encodes the large sarcolemmal protein dystrophin. The spectrum of phenotypes includes the severe, early-onset Duchenne muscular dystrophy (DMD) (1:4,000 to 1:6,000 live male births) (10), the milder and later onset Becker muscular dystrophy (BMD) (1:18,000 live male births) (11), as well as the mild forms with muscle cramps and myoglobinuria and the asymptomatic hyperCKemia form (12). Finally, the muscle can be clinically spared in XLR-DCM (**Figure 1**).

Duchenne muscular dystrophy. DMD is diagnosed in the pediatric age group, and neurologists and pediatricians provide their main care. Affected children are referred to cardiology with an established clinical and genetic diagnosis. The pathologic hallmark is the absence of dystrophin in the skeletal myocyte sarcolemma (12). Genetic defects consist of either large rearrangements (>70% of cases, frequently out-of-frame deletions) or point mutations, truncation-predicting null mutations, or less commonly, missense mutations. Genetic testing provides nearly 100% positive results. In two-thirds of cases, the disease is inherited (10). All DMD patients require regular cardiologic care from the point of initial diagnosis (6,7,13). In addition to neurologists and cardiologists, expanded multidisciplinary teams may include pulmonologists, orthopedists, physiatrists, gastroenterologists, and dieticians (9).

The cardiac manifestations could be subtle in wheelchair-bound patients with little demand on the heart. The prevalence of DCM increases with age, and imaging studies demonstrate cardiac involvement in nearly all young adult patients (14–18). Early resting electrocardiography (ECG) changes include right axis deviation, Q waves in the left precordial leads, and conduction defects (14,15). Diagnosis of DCM is based on transthoracic echocardiography; when feasible, cardiac magnetic resonance (CMR) may provide additional information about the left ventricular (LV) wall structure (adipose and fibrous replacement) and LV trabecular anatomy (16). Patients must be followed regularly at least with annual echocardiograms (10). Treatment is based on heart failure (HF) guidelines and disease-specific recommendations (6,7). Although current DMD guidelines recommend treatment with angiotensin-converting enzyme (ACE) inhibitor in patients with established LV systolic dysfunction (10), ACE inhibitor can be beneficial before the development of LV systolic dysfunction in patients with DMD (by 10 years of age) (19); patients who cannot tolerate an ACE inhibitor can be treated with an angiotensin receptor blocker, which is as effective as an ACE inhibitor in DMD. End-stage evolution depends on the combination of respiratory muscle involvement, skeletal deformation, and DCM (18). These multiple contributors to cardiorespiratory failure preclude heart transplantation (HTx). Ventricular assist device implantation used as destination therapy may help prolong survival in these patients (20). Steroid treatment, spinal stabilization surgery, nocturnal ventilation, and physiotherapy have contributed to an increase in life expectancy from the late 20s (17) to early 40s (21), highlighting the need for continuity and intensity of cardiac care.

Becker muscular dystrophy. Generally, in BMD patients, DCM clinically manifests in the second to fourth decade of life; however, DCM can be diagnosed

FIGURE 1 Cardiodystrophinopathies

A

Apparently sporadic DCM, *DMD* Del 48-51 in frame, DCM phenotype, end-stage

III:2, $M_0\,O_0\,G_{Neg}\,E_{G\text{-}DMD[neg]+LMNA[neg]}\,S_{C\text{-}II}$
III:3 → $M_{D(>sCK)}\,O_{H+M}\,G_{XLR}\,E_{G\text{-}DMD[Del\ exons\ 48\text{-}51\ hemizygous]+LMNA[p.Leu587Leu]}\,S_{C\text{-}II\ evolved\ to\ IV}$
IV:3, $M_0\,O_0\,G_{XLR}\,E_{G\text{-}DMD[Del\ exon\ 48\text{-}51\ heterozygous]}\,S_{A\text{-}I}$

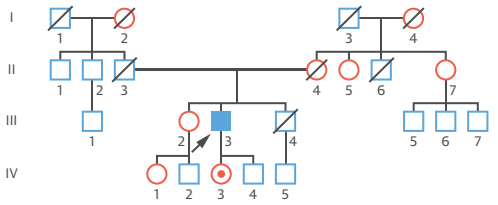

Family History

I:1-4 paternal and maternal family history negative
II:3 death at age 57, gastric cancer
II:4 death at age 77, complications of femoral fracture
II:5 and II:7, clinically healthy, non-carriers
III:1 age 47, negative clinical evaluation, normal sCK
III:2 healthy, non-carrier
III:3 → age 29 DCM onset; age 39 HTx
III:4 death at age 25, trauma; unknown genetic status
IV:3 age 6; IV:4, age 2. Both children are healthy

The heart excised at transplantation

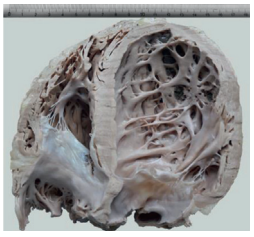

Severely dilated left ventricle with mural thrombosis

B

De novo – Becker phenotype - MOGE(S) Proband II:1 → $M_{D(>sCK)}\,O_{H+M}\,G_S\,E_{G\text{-}DN\text{-}DMD[p.Arg1763X]}\,S_{C\text{-}I}$

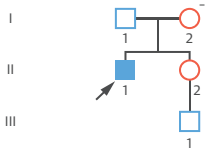

I:1 negative clinical evaluation
I:2 negative clinical evaluation and genetic test
II:1 → age 14, **>sCK**
age 25, 2D-TTE: LVEDD 55mm; LVEF 52%
Sanger sequencing: *de novo DMD* p.(Arg1763X)
II:2 healthy

EMB Healthy Ctrl DYS-Immunostain

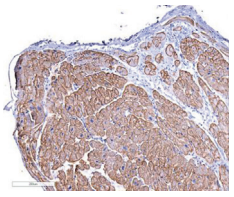

EMB XL-DCM DYS-Immunostain

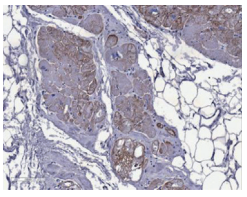

C

Slowly progressing, inherited BMD with mildly dilated DCM. MOGE(S) Proband III:1 → $M_{D(>sCK)}\,O_{H+M}\,G_{XLR}\,E_{G\text{-}DMD[Del\ exons\ 45\text{-}48\ hemizygous]}\,S_{C\text{-}II}$

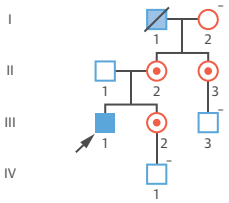

I:1 age 56, HF
I:2 age 86, non-carrier
II:1 age 53, healthy
II:2 age 51 , healthy carrier
II:3 age 47, healthy carrier
III:1 → age 8, muscle weakness , **>sCK**, BMD diagnosis
age 19, first detection of mild LV dilation, LVEF 50%
Overall follow-up for 24 years in OMT: stable LVEDD 52mm, LVEF 54%
Undulating **sCK** levels, with max values **2553 U/L**
III:2 age 17, healthy carrier, current age 29
IV:1 age 3, non-carrier

Last 2D-TTE, age 32

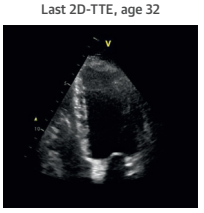

Last ECG, age 32

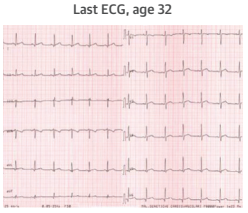

D

Duchenne phenotype. MOGE(S) Proband III:1 → $M_{D(>sCK)}\,O_{H+M}\,G_{XLR}\,E_{G\text{-}DMD[Del\ exons\ 48\text{-}52\ hemizygous]+MYH7[p.Lys1459Asn]}\,S_{C\text{-}I}$

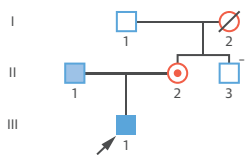

I:1 age 80, healthy
I:2 age 62, colon cancer
II:1 age 55, LVH (LV thickness 12 mm)
II:2 age 47, healthy carrier, normal CK (<180U/L)
II:3 age 45, healthy, non-carrier
III:1 → severe DMD, chair-bound since the age of 11; ECG: LVH; LVEDD 44mm; LVEF 45%; last follow-up at age 27, clinically stable.

II:1 $M_{(E[H])}\,O_H\,G_U\,E_{G\text{-}MYH7[p.Lys1459Asn]}\,S_{B\text{-}I}$
II:2 $M_0\,O_0\,G_{XLR}\,E_{G\text{-}DMD[Del\ exons\ 48\text{-}52\ heterozygous]}\,S_{A\text{-}I}$

Interpretation:
The effect of the *MYBPC3* variant (VUS): the unusual ECG pattern (LVH) in III:1 and the mild LVH in the father suggest a possible modifier effect of the *MYH7* gene variant.

The figure illustrates 4 typical examples of patients referred to cardiovascular attention for dystrophinopathy. **(A)** XLDCM; **(B)** de novo BMD with DCM as the major clinical phenotype; **(C)** mild and slowly progressing DCM in BMD; **(D)** wheelchair-bound DMD patient. Phenotypes and genotypes are shown according to the MOGE(S) nosology (8). → = proband; 2D-TTE = 2Dimensional Transthoracic echocardiogram; BMD = Becker muscular dystrophy; Ctrl = control; DCM = dilated cardiomyopathy; DMD = Duchenne muscular dystrophy; DYS = dystrophin; EMB = endomyocardial biopsy; HF = heart failure; HTx = heart transplantation; LV = left ventricle; LVEDD = left ventricular end-diastolic diameter; LVEF = left ventricular ejection fraction; LVH = left ventricular hypertrophy; MOGES = M is morphofunctional characteristics, O is organ involvement, G is genetic or familial inheritance pattern, E is etiological information, and S is functional status; OMT = optimal medical therapy; sCK = serum creatine kinase; XL = X-linked.

in childhood in patients recognized as affected by BMD (22). The skeletal muscle phenotype is variable and, in any case, milder than that in DMD. Therefore, patients remain ambulatory until advanced adult age (10–12). Dystrophin mutations in BMD are more frequently in-frame deletions and result in variably decreased expression of the protein (23). DCM occurs in most patients and can be the first clinically overt

manifestation of the disease (24). However, hyperCKemia is common and should be considered a sufficient reason for consultation with a neurologist. The onset of DCM is subtle, and the progression of LV systolic dysfunction is either slow, wherein the patient may remain stable with New York Heart Association functional class I to II symptoms, or fast, wherein even trivial external triggers such as influenza-like febrile episodes may substantially worsen the clinical condition (23–25). Patients with BMD-DCM are treated with HF medications and devices according to the guidelines (6,7,26). HF is the most common cause of end-stage disease and may constitute an appropriate indication for HTx (6,7,26); post-transplantation outcome is similar to that of (non-BMD) idiopathic DCM (7).

X-linked recessive dilated cardiomyopathy. XLR-DCM is the unique, clinically overt manifestation of *DMD* gene defects in a small proportion of dystrophinopathies (27). Prevalence ranges from 3% to 7% in consecutive male patients with nonpaternally inherited DCM (28,29). HyperCKemia is almost always present (>80%), but patients have no history or symptoms of muscular dystrophy. The rare XLR-DCM is caused by mutations that affect the muscle promoter and the first exon of the gene, resulting in absent expression of dystrophin in cardiac myocytes. In skeletal muscle, the activation of 2 alternative promoters (the brain and Purkinje cells promoters) results in expression of dystrophin levels that are sufficient to prevent skeletal muscle dystrophy (30). Alternatively, DCM can be caused by partial loss of protein epitopes that are functionally relevant to the cardiomyocyte sarcolemma (30,31). A large number of patients with adult-onset dilated cardiodystrophinopathy carry deletions of the rod or mid-rod domain of the protein, which is essential for cardiac function. Earlier DCM was reported to occur in carriers of defects of the amino-terminal domain of the protein (32). Clinical management is based on indications for HF, including transplantation, which has the same outcome as that of BMD-DCM (33,34).

Muscle cramps and myoglobinuria. Patients with muscle cramps and myoglobinuria and those with asymptomatic hyperCKemia do not demonstrate DCM (10,12), but these traits are useful markers for suspecting *DMD* mutation-related disease, especially when identified in relatives of male patients with still uncharacterized DCM. Cardiac monitoring is to be provided regularly.

Female carriers may demonstrate isolated hyperCKemia; DCM may occur in adult and advanced ages; mothers, aunts, and older sisters of DMD-DCM patients should undergo periodic monitoring and are managed according to contemporary guidelines (6,7,13,26).

LIMB GIRDLE MUSCULAR DYSTROPHY. DCM is the most common cardiac phenotype in LGMD (35). The weakness and wasting of pelvic and shoulder girdle muscles characterize this heterogeneous group of disorders in which skeletal, respiratory, gastrointestinal, and nervous systems may be variably involved (Online Table 1). The genetic heterogeneity of LGMD makes the classification complex and explains the difficulties that cardiologists may encounter in grouping these patients on the basis of phenotype and cause. The classification has been recently modified from the original clinically based description (36) to the novel gene-based nosology (37). The clinical descriptor LGMD is followed by a number that distinguishes between the 2 major groups of autosomal dominant (AD) LGMD type 1 (LGMD1) and the autosomal recessive (AR) LGMD type 2 (LGMD2) diseases, complemented by letters that correspond to the mutated protein/gene (37). More than 30 subtypes of LGMD are known and are caused by defects in proteins that are involved in different molecular pathways and cellular structures: dystrophin-associated glycoproteins, nuclear structures, sarcomeres, Z-bands, molecular trafficking, and signal transduction pathways (38).

The prevalence of LGMD varies also due to the founder mutations in some populations (39). Current estimates range from 1:14,500 to 2.27:100,000 (40,41). Cardiac and respiratory impairments are common, especially when ambulation is lost. The prevalence of DCM varies in the different subgroups of patients; for example, more than one-third of patients with (α-, β-, δ-, and γ-) sarcoglycanopathies develop DCM (42). The malignancy and risk of sudden death are also variable. For example, LGMD1B (laminopathy) is associated with DCM, conduction defects, and high risk of sudden death (43). Up to 50% of patients with LGMD2I (fukutinopathies) develop DCM as well as substantial respiratory function impairment due to diaphragmatic weakness (44). HyperCKemia is common, although results for disease-specific biomarker tests can vary according to the cause. Cardiac and muscle imaging and functional studies include routine echocardiography and CMR for the cardiomyopathy and electromyography, muscle ultrasonography, and CMR imaging for characterization of the affected skeletal muscles (45,46). Monitoring in multidisciplinary settings is scheduled for each patient and family according to the patient's clinical needs. Medications include steroids with variable

FIGURE 2 LGMD1B Caused by Mutation in the *LMNA* Gene

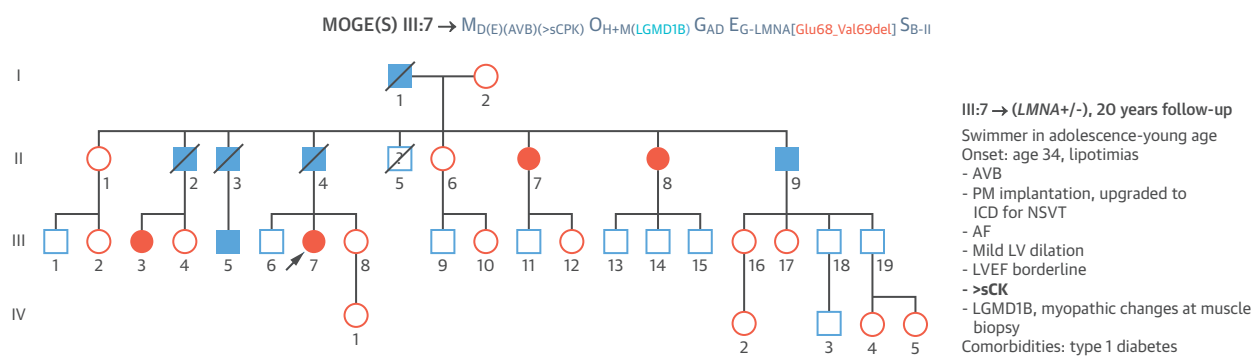

Family History

I:1 SD at age 42, (*LMNA*+/-), obligate carrier
I:2 age 92, genetic test: negative
II:1 clinical and genetic screening: negative
II:2 SD at age 39, obligate carrier (*LMNA*+/-); unknown status of the skeletal muscle
II:3 SD at age 37, obligate carrier (*LMNA*+/-); unknown status of the skeletal muscle
II:4 onset at age 41, (*LMNA*+/-); AVB (PR 320msec), LGMD, DCM. Comorbidities: diabetes, hypertension, CAD: 3-Vessel-Disease; 2 AMI. Death at the age of 61 due to IHD
II:5 death at the age of 15; no information
II:6 clinical and genetic screening: negative
II:7 onset with AF; (*LMNA*+/-); AVB; **>sCK**, muscle weakness; noncontractural muscle dystrophy, LGMD clinically diagnosed; DCM; stable with mild LV dilation and dysfunction
II:8 onset with AF; (*LMNA*+/-); AVB, **>sCK**, myopatic changes at muscle biopsy, LGMD clinically diagnosed, DCM (19 years follow-up)
II:9 onset with AVB; (*LMNA*+/-); **>sCK**, LGMD clinically diagnosed; mild DCM (17 years follow-up); Comorbidities: hypertension, diabetes
III:3 (*LMNA*+/-); AVB, **>sCK**, LGMD, normal LV size and function
III:4 clinical and genetic screening: negative
III:5 (*LMNA*+/-); AVB, **>sCK**
III:6 clinical and genetic screening: negative
III:8 clinical and genetic screening: negative
III:11-III:13 clinical and genetic screening: negative
III:14 age 19 at first screening, (*LMNA*+/-); healthy carrier
III:16, III:18, III:19 clinical and genetic screening: negative
III:17 age 21 at first screening, (*LMNA*+/-); healthy carrier

Pedigree of a family with noncontractural LGMD1B caused by an in-frame *LMNA* mutation associated with DCM, AF, and AVB. The cause of the muscle dystrophy was unknown before discovery of the *LMNA* gene mutation. Comorbidities in II:4 highlight the importance of continuous cardiovascular follow-up in these patients. Three family members died suddenly. AF = atrial flutter; AMI = acute myocardial infarction; AVB = atrioventricular block; CAD = coronary artery disease; EF = ejection fraction; IHD = ischemic heart disease; LGMD = limb girdle muscular dystrophy; NSVT = nonsustained ventricular tachycardia; PM = pace maker; PR = electrocardiography PR interval; SD = sudden death; >sCK = hyperCKemia; SWTd = septum wall thickness diastole; other abbreviations as in Figure 1.

effectiveness (46). Patients with DCM, arrhythmias, and conduction defects are treated according to contemporary guidelines (6,7,26,35) as there are no currently actionable targeted therapies. In patients with clinical indications for HTx (mild dystrophy and spared respiratory muscles), mechanical circulatory support can be considered as a bridge to HTx (35).

Autosomal dominant LGMD. LGMD1 (Online Table 1A) includes 8 forms, 7 with known disease genes, and 1 with an unknown disease gene. DCM has been reported to date in at least 4 forms and is in the context of phenotypes that are well known by cardiologists: myotilinopathies (47), laminopathies (48), caveolinopathies (49), and desminopathies (50). *CAV3*-associated cardiomyopathy is currently described as hypertrophic cardiomyopathy (HCM) (51); however, the clinical descriptions of published cases suggest DCM rather than HCM (49,51,52). The age of onset is variable, with frequent manifestations in childhood or adolescence (46). A clinician may consider an implantable cardioverter-defibrillator (ICD) regardless of the muscular involvement in the LGMD1B disease due to the high risk of sudden death (**Figure 2**).

Autosomal recessive LGMD. LGMD2 (Online Table 1B) is caused by defects in 1 of the currently known 25 different genes, sharing a similar skeletal muscle phenotype characterized by progressive weakness and wasting of the shoulder and pelvic girdle muscles (37,38). DCM occurs in variable proportions in these different entities. The specific diagnosis is obtained with genetic testing or may be suspected by immunostaining of skeletal muscle biopsy sample (46). The prevalence of every LGMD2 form varies in different ethnic populations (39). The age of onset may range from the first years of life up to the fifth decade but onset occurs more frequently in the second to third decades. Patients

may develop joint contractures and respiratory failure and demonstrate involvement of the gastrointestinal tract, central nervous system and skeletal system, all conditions critically influencing the outcomes and medical decisions (44,46).

EMERY-DREIFUSS MUSCULAR DYSTROPHY. EDMD may be suspected in patients with DCM, conduction disease, hyperCKemia, and variable contractural dystrophy. Joint contractures (elbows, ankles, and cervical spine) occur early, and skeletal muscle weakness is slowly progressive (53). The disease is caused by mutations in genes that encode nuclear envelope proteins (Online Table 2). Inheritance is XLR (*EMD* [54] and *FHL1* [55] genes), AD (*LMNA* [56], *SYNE1* [nesprin1] [57], *SYNE2* [nesprin2] [58], and *TMEM43* [59] genes) and less commonly, AR (*LMNA* gene [60]). Approximately 50% of patients with the diagnosis of EDMD carry mutations in genes encoding emerin, lamin A/C, nesprin1 and nesprin2 (53). These proteins are constituents of the nuclear envelope linker complex, which connects the nucleoskeleton to the cytoskeleton (61).

EDMD cardiomyopathy is typically dilated and hypokinetic and frequently associated with atrioventricular (AV) conduction disease (53). The exception is the XLR *FHL1*-associated EDMD in which the most common cardiac phenotype is HCM with conduction defects and arrhythmias. Variants characterized by mild hypertrophy with systolic dysfunction and restriction, nondilated ventricles, possible QTc prolongation, fibrofatty replacement, and scarring and prominent LV trabeculations have been described (62,63). In XLR emerinopathies, the AV conduction defects and arrhythmias, mostly of atrial origin, may appear before LV systolic dysfunction. Patients are commonly referred to cardiologists for arrhythmia consultation and consideration of pacemaker implantation (64,65). One of the described cardiac phenotypes in XLR emerinopathies is atrial standstill (66), a condition that requires prevention of systemic embolism. The risk of ventricular arrhythmias is high in AD EDMD, caused by mutations in the *LMNA* gene (65). The last entry, the *TMEM43* gene (EDMD7), is associated with noncontractural muscle dystrophy, with only 2 cases reported to date (59). Management is nonspecific for DCM, arrhythmias, and conduction disease and is based on HF guidelines; however, stratification of arrhythmogenic risk should take into account the disease-causing gene, the type of mutation (4), and the guidelines for primary prevention of sudden death that now include the genotype (67).

HCM PHENOTYPES

The major groups of skeletal muscle diseases manifesting with LV wall thickening as the cardiac phenotype include clinically and genetically heterogeneous metabolic disorders, in which the mechanisms causing LV hypertrophy differ from that of sarcomeric HCM. Friedreich ataxia (FRDA) and mitochondrial myopathies are characterized by impaired synthesis and use of energy substrates, with proliferation of abnormal organelles. In glycogen storage diseases the use of energy substrates is impaired, leading to intracellular accumulation.

FRIEDREICH ATAXIA. HCM is the typical cardiac phenotype observed in patients with FRDA, a rare (1:50,000 prevalence) AR neuromuscular disease caused by homozygous GAA expansions in the first intron of the *FXN* gene (Ch.9q21.11) (96% to 98%) (68) or by compound heterozygous expansion associated with a point mutation or an exonic deletion (2% to 4%) (69). The *FXN* gene encodes frataxin, a mitochondrial protein of iron homeostasis. Frataxin deficiency impairs and dysregulates mitochondrial iron trafficking (70). The GAA triplet expansion leads to transcriptional gene silencing and loss of frataxin expression (71). In normal unaffected individuals, repeat expansions are usually <12 but can range from 12 to 59 (68). In patients with Friedreich ataxia, the number of repeat expansions increases to 60 to 1,500 (72).

In addition to the characteristic features of spinocerebellar ataxia, the heart may also be affected, and patients may experience a hypertrophic cardiomyopathy.

Clinical onset of FRDA occurs in the first or second decade of life (69–72). The disease is clinically characterized by cerebellar ataxia, dysarthria, HCM, diabetes, neurosensory hearing loss, and visual impairment. Mean survival is approximately 40 years (73). Predictors of death include age at onset, number of repeat expansions, disease severity, and HCM (72,74). The HCM is characterized by symmetrical nonobstructive hypertrophy, diastolic dysfunction, and progression to systolic dysfunction (73–75). Pathologic studies demonstrate iron deposits in mitochondria (70). ECG, 24-h Holter ECG, speckle tracking of 2D-TTE, CMR with late enhancement imaging to identify fibrosis, and measurement of high-sensitivity troponin-T concentration have demonstrated cardiac involvement in >90% of patients, in whom approximately 40% demonstrate supraventricular tachycardia (76–78). Antioxidants

FIGURE 3 MtDNA deletion-related Kearn Sayre Syndrome

MtDNA deletion-related Kearn Sayre Syndrome (KSS) with mild symmetrical, non-obstructive HCM and clinical history of ventricular arrhythmias

MOGE(S) nosology and pedigree

III:2 → $M_{H(>sCK)}$ O_{H+M+E} G_S $E_{G\text{-}mtDNA[Macrodeletion\ nt6324\text{-}76665]\ +\ SCN3B[p.Leu10Pro]}$ $S_{C\text{-}II}$
III:1 M_0 O_0 G_N $E_{0\ SCN3B[Neg]}$ $S_{C\text{-}II}$
II:2 and II:3 not tested

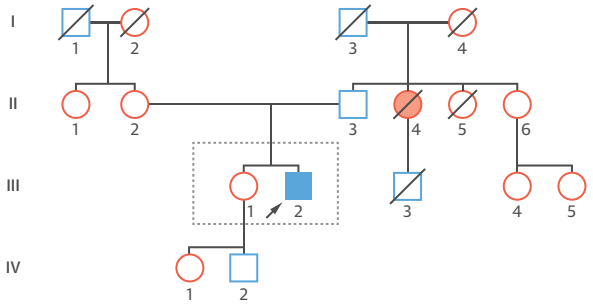

Familial history - Incomplete family screening

I:1 death at age 79
I:2 death at age 90
I:3 death at age 89
I:4 death at age 99
II:1 age 79, bullous pemphigoid, HCV +
II:2 age 74, bullous pemphigoid
II:3 age 82, hypercholesterolemia
II:4 SD at age 40
II:5 death at age 60, leukemia
II:6 age 76
III:1 age 52, negative clinical screening
III:2 → age 52, KSS
III:3 death at age 19, unknown cause
III:4 and III:5: healthy
IV:1 and IV:2: healthy

III:2 →, Proband clinical history

Age 34, KSS diagnosis

Heart: HCM, arrhythmias

- **>sCK (600 U/L)**
- Retinitis pigmentosa with worsening visual loss
- Ophthalmoplegia
- Palpebral Ptosis
- Myalgia
- Iatrogenic hepathic steatosis (Idebenone)
- Neurosensorial hearing loss

Surgical interventions:
- varicocele
- blepharoplasty

III:2 → Cardiac data

2D-TTE, age 52	**Arrhythmias**
LVEDD 53mm	Age 43, palpitations
LVEF 53%	24-H ECG 8000 PVB
SWTd 15mm	
LV PWTd 15mm	Age 46,
	24-H ECG 4845 PVB
ECG	
SR, 70bpm	Electrophysiological study: negative
PR 180msec	
QRS 152 msec	Age 52,
cQT 461 msec	Frequent, isolated PVB
RBBB + LAFB	

2D-TTE – PSAX | 2D-TTE – 4-Chamber - Diastole | 2D-TTE – 4 Chamber - Systole

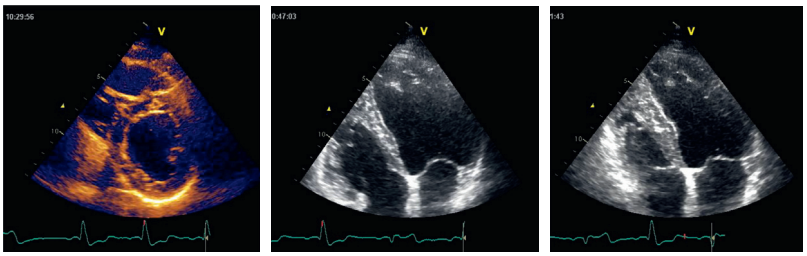

In this patient, the cardiac phenotype is characterized by symmetrical, nonobstructive HCM and arrhythmias. Both traits could be explained by the mitochondrial defect, but the *SCN3B* defect could contribute to the arrhythmic phenotype, even in the absence of a Brugada pattern on ECG. 24-H ECG = 24-h ambulatory electrocardiography monitoring; cQT = corrected QT interval; HCM = hypertrophic cardiomyopathy; HCV+ = hepatitis C virus infection; LAFB = left anterior fascicular block; LVEDD = left ventricular end-diastolic diameter; PSAX = parasternal short axis; PVB = premature ventricular beats; PWTd = posterior wall thickness, diastole; RBBB = right bundle branch block; SR = sinus rhythm; other abbreviations as in **Figures 1 and 2**.

and iron chelators are used in FRDA patients, but evidence of chelator benefits is debated (79,80). HTx is a potential option for end-stage cardiomyopathy but is limited to few patients because of the complex systemic nature of the disease and is feasible in patients with cardiac dysfunction with mild or no neurologic dysfunction (81).

MITOCHONDRIAL MYOPATHIES AND CARDIOMYOPATHIES. Mitochondrial diseases result from deficiencies in the mitochondrial oxidative phosphorylation (OXPHOS) system, a ubiquitous cellular function that consists of 5 multisubunit enzyme complexes (I to V) (82). The overall estimated prevalence is 1:4,000 (82,83). These diseases commonly involve both the heart (mitochondrial cardiomyopathies) and the skeletal muscle (mitochondrial myopathy) but also cause hearing loss, ocular disorders, cryptogenic stroke, gastrointestinal diseases, renal failure, and diabetes. Depending on the genetic cause, namely defects in mitochondrial DNA (mtDNA) or nuclear genes, the inheritance is matrilinear or Mendelian, respectively (83) (Online Tables 3A and 3B). mtDNA genes encode 13 OXPHOS proteins, 22 transfer RNAs, and 2 ribosomal RNAs. Although their products are approximately 1% of the overall OXPHOS proteins, their defects cause 15% of human mitochondrial diseases (83). Nuclear genes encode >1,500 proteins, which constitute >99% overall OXPHOS proteins; their defects cause most human mitochondrial diseases. The simplest molecular classification (84) includes either disorders due to mutations in mtDNA (maternally inherited point mutations and sporadic large scale deletions) (**Figure 3**) or disorders due to mutations in nuclear DNA (Mendelian/autosomal inheritance). The five OXPHOS complexes are made of many different components, each of them contributing to the overall function of 1 or more of the 5 complexes. Therefore,

phenotype similarities (e.g., Leigh syndrome or mitochondrial depletion syndromes [Online Table 3C]) are explained by the failure of 1 (or >1) OXPHOS complexes when defects affect ubiquitous functions, whereas differences are probably explained by the dose (or amount) of the defective system/complex in organs with different energy demands.

mtDNA defects. The most common cardiac phenotype is concentric, nonobstructive LV hypertrophy, potentially evolving to LV dilation and dysfunction (85,86). A short PR interval and pre-excitation can be associated with the cardiomyopathy and constitute useful ECG markers for suspecting a mitochondrial disease (87). Mitochondrial defects, however, rarely present with isolated heart or skeletal muscle involvement (82,84). The clinical manifestations depend on the degree of somatic heteroplasmy. The variable amount of mutated mtDNA in the different organs and tissues explains why clinical phenotypes differ in family members who share the same mtDNA mutation (88). MELAS (mitochondrial myopathy, encephalopathy, lactic acidosis, and stroke) is one of the malignant mitochondrial disorders and is predominantly caused by mutations in the mtDNA genes encoding transfer RNAs (89). The most common mutation, c.3243A-G in the *MTTL1* ($tRNA^{Leu(UUR)}$) gene, can be present at low levels in many asymptomatic individuals (~1:300 in the general population) and at high levels in affected individuals (~1:5,000) (88,89). When cardiomyopathy is the main or early clinical manifestation, patients are first referred to cardiologists (**Figure 4**). However, if the clinical context is not taken into consideration, the risk of misdiagnosis may be high (e.g., sarcomeric HCM, cardiac amyloidosis or even Anderson-Fabry disease). mtDNA-related diseases are potentially lethal, and death most commonly occurs due to recurrent stroke-like episodes, HF, and renal failure (90).

Nuclear DNA defects. With more than 1,500 mitochondrial proteins encoded by nuclear genes, the number of novel diseases is constantly increasing (90). Neurologists play a leading role in these scientific and clinical advancements, which introduce new cardiac scenarios where cardiomyopathies and arrhythmias represent the potential determinants of prognosis. The classification of nuclear mitochondrial myopathies is currently based on both phenotype and cause (82,83). HCM is the most common cardiac phenotype, followed by DCM, RCM, and arrhythmogenic cardiomyopathy (90). LV trabeculae can also be prominent (3,91). Involvement of nonstriated muscle can clinically manifest with dysphagia and gastrointestinal symptoms (92). The inheritance is mainly AR, with clinical onset from pediatric to juvenile ages. Genetic testing provides precise diagnoses when guided by a clinical hypothesis (93). Novel entities, such as the "cardiomyopathy and lactic acidosis syndrome," are diseases of cardiologic pertinence (94). Lactic acidosis is reported in 100% and HCM in 80% of patients with mtRNA translation optimization 1 (MTO1) deficiency; MTO1 is an evolutionarily conserved protein expressed in high-energy demand tissues (95), and its deficiency is potentially lethal, especially in early onset multisystemic forms. Genetic testing provides the basis for genotype-phenotype correlation, which may explain the different intensities of disease severity (95).

GLYCOGEN STORAGE DISORDERS. The description of novel glycogenosis (glycogen storage disorder [GSD] type XV), screening studies (newborn and populations at risk), and the wide application of next generation sequencing have modified the prevalence of GSD, in addition to the existence of late-onset phenotypes that were previously undiagnosed (96). These new data have cardiac relevance because both skeletal muscle and heart are involved in the major GSDs (97,98), including type 2 (Pompe disease), type 2b (Danon disease), type 3 (Cori disease or Forbes disease), type 4 (Andersen disease), type 5 (McArdle disease), type 7 (Tarui disease), and type 9 (phosphorylase kinase deficiency). This latter disease includes isolated fatal infantile forms (99) (Online Table 4). Each is a rare disease, but collectively, they are relatively common. Pompe disease and McArdle disease are the most frequent forms, with recent estimates indicating a prevalence of approximately 1:40,000 people, respectively (100,101).

AR Pompe disease. GSD type II is caused by a deficiency of alpha1,4 glucosidase, encoded by the *GAA* gene (97,101). Heart, skeletal muscle, and liver are the target organs of glycogen accumulation. In the heart, the enzyme defect causes progressive lysosomal glycogen accumulation that thickens the myocytes and myocardial walls, impairs diastolic relaxation (diastolic dysfunction), and irreversibly damages myocytes, causing systolic dysfunction and HF (97). HCM is the main cause of death in the infantile form; infants may have HCM, an enlarged tongue, and severe skeletal muscle hypotonia (floppy babies), with the liver remaining normal in size. The ECG shows large QRS complexes and short PR intervals (97). Without specific enzyme replacement treatment, the disease is rapidly fatal. The heart is less commonly

FIGURE 4 Cardiomyopathy in MELAS

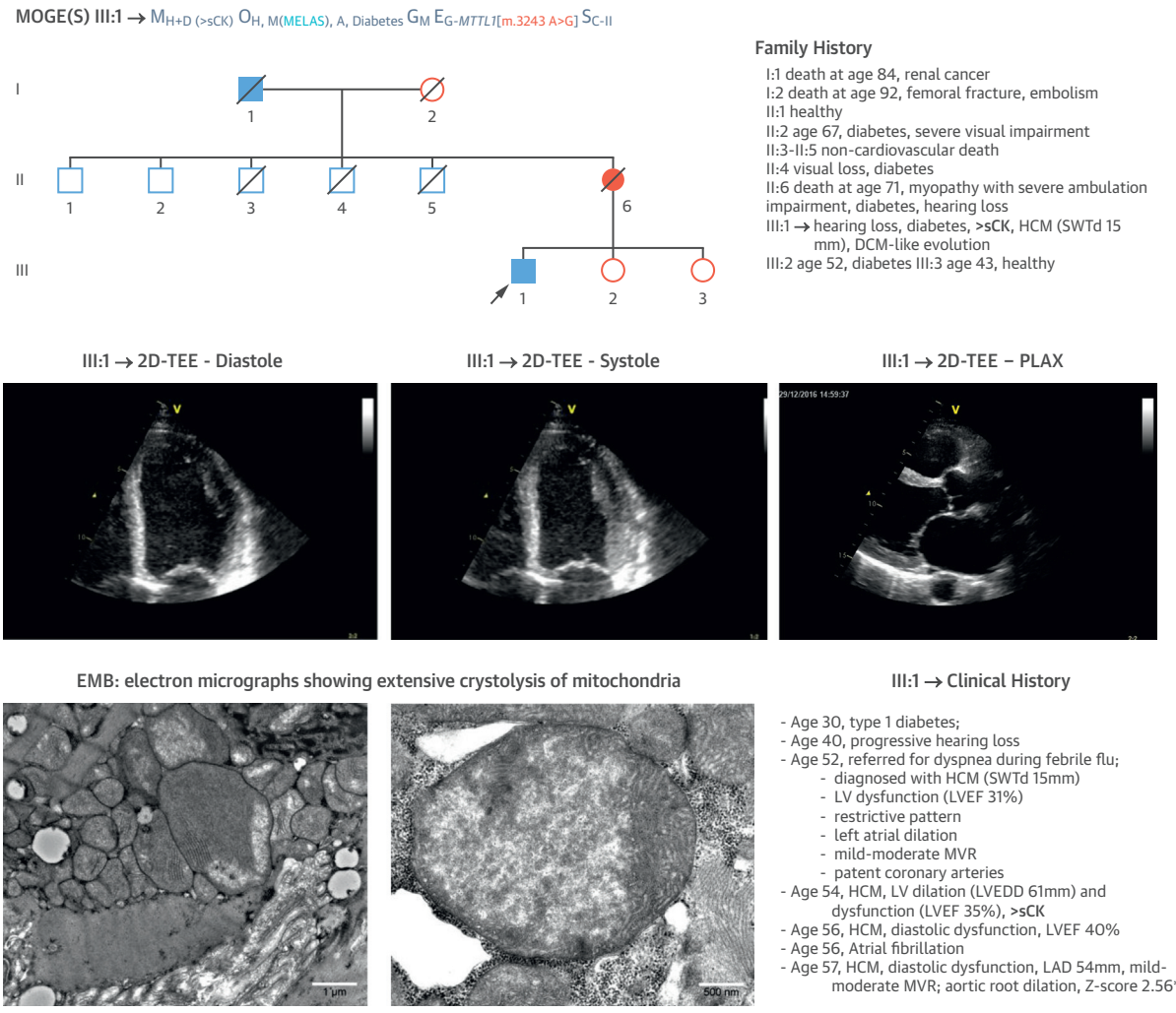

Pedigree and 2D-TTE views of the LV in a male patient with MELAS caused by the classical *MT-TL1*[3243A>G] mutation. *According to Roman et al. (181). EMB = endomyocardial biopsy; HCM = hypertrophic cardiomyopathy; ICD = implantable cardioverter defibrillator; LAD = left atrial diameter; MELAS = mitochondrial myopathy, encephalopathy, lactic acidosis, and stroke; MVR = mitral valve regurgitation; other abbreviations as in **Figures 1 to 3**.

involved in juvenile forms. Motor milestones are delayed, and the myopathy gradually worsens, especially in the limb girdle and truncal muscles. Without enzyme replacement treatment, death occurs from respiratory failure before adulthood (97,101). Adult onset or late-onset Pompe disease (LOPD) is the most common form of GSD II, usually presenting between the third and the fourth decades of life (102). Signs and symptoms of illness may be triggered by fasting and include exercise intolerance and fatigue, myalgia, cramps, and stiffness in the absence of contractures. Arterial aneurysms are possible and are caused by glycogen storage in vascular smooth muscle cells (103). Patients with LOPD are referred to neurologists because of the prevalent skeletal muscle-related symptoms and post-exercise rhabdomyolysis with episodes of pigmenturia. Mild and nonspecific cardiac abnormalities are detectable by CMR only in a small proportion of patients with LOPD (102). Skeletal muscle or endomyocardial biopsy can be useful, but the diagnosis can be achieved non-invasively, with the dosage of enzyme activity and genetic testing. HCM, when present, can be stable, and the disease may have a slowly progressive course, especially in patients treated with enzyme replacement treatment (102).

FIGURE 5 Cardiomyopathy in Danon Disease

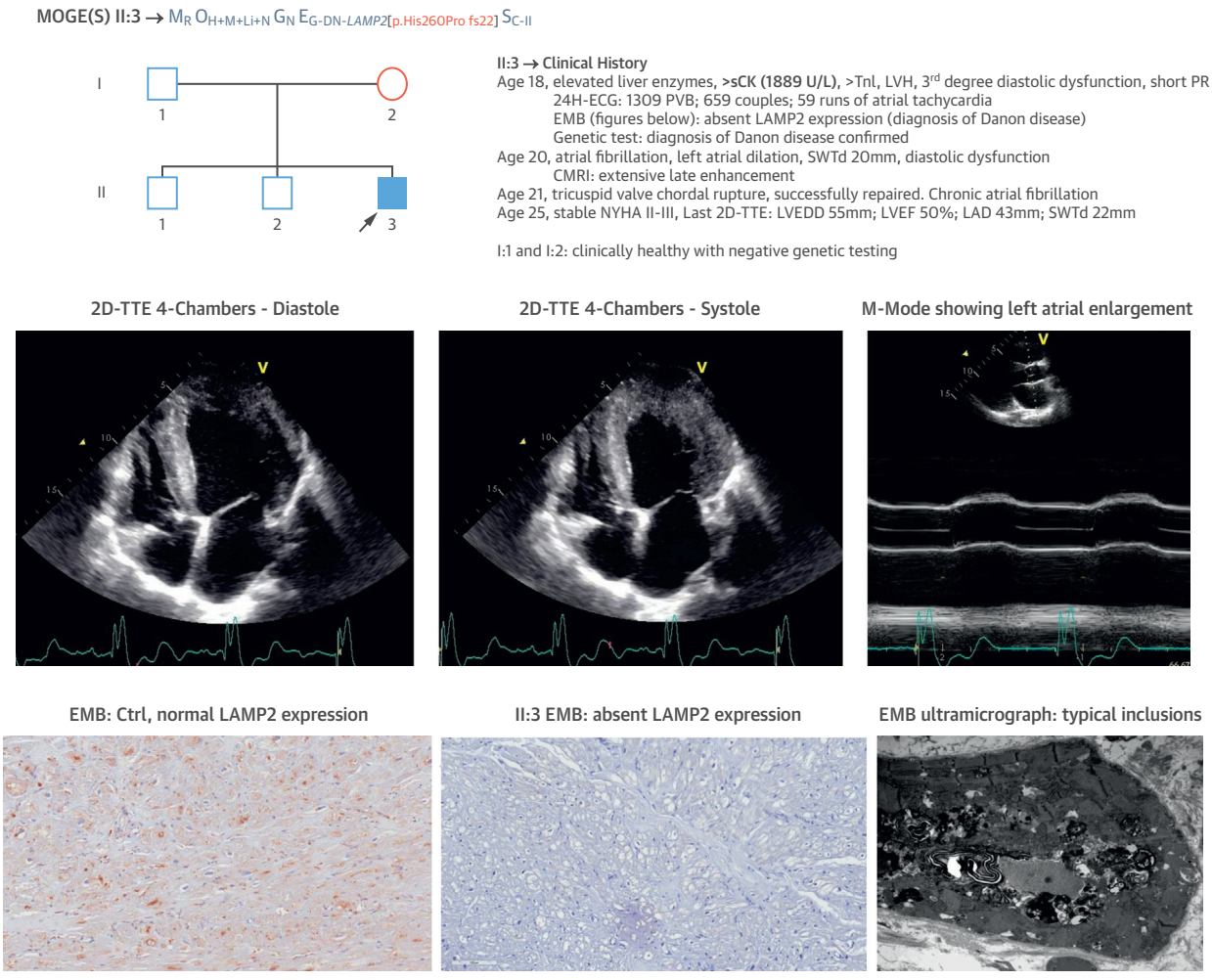

The young male patient with Danon disease caused by a de novo mutation in the *LAMP2* gene had HCM, myopathy, and mild cognitive impairment. Endomyocardial biopsy demonstrated absence of the mutated protein. CMRI = cardiac magnetic resonance imaging; *LAMP2* = lysosome-associated membrane protein 2 gene; NYHA = New York Heart Association; >TnI = troponin I elevation; other abbreviations in Figures 1 and 2.

XLD Danon disease. GSD II type 2b is a rare multisystemic disorder caused by mutations in the *LAMP2* gene, which encodes the lysosome-associated membrane protein 2. In male patients, the phenotype is characterized by early-onset, severe biventricular HCM with evolution through systolic dysfunction, skeletal muscle disease with hyperCKemia, and cognitive impairment. In female patients, the HCM is later-onset but severe. Tall QRS voltages, short PR, and pre-excitation are common ECG findings. 2D-TTE shows severe LVH with possible prominent trabeculae and evolution through LV thinning and systolic dysfunction. CMR demonstrates extensive fibrosis in end-stage hearts. There is no treatment, and patients are cared for according to phenotype (104). HTx may be successfully performed with post-transplantation outcome similar to that of other cardiomyopathies (104) (Figure 5).

AR McArdle disease. GSD type V can manifest in late childhood or in early teens with cramps, myalgias, and skeletal muscle weakness, which is worsened with exertion and relieved following rest. Strenuous exercise may result in prolonged pain and cause episodes of rhabdomyolysis (105). An individual overcoming the initial symptoms without interruption in exercise can continue with prolonged activity as other forms of energy (fatty acids) are mobilized ("second wind" phenomenon). The disease

FIGURE 6 McArdle Disease Complex Genotype

MOGE(S) nosology of family members

I:1 age 71, $M_{E[D]}$ O_H G_{AD} $E_{G\text{-}TTN[p.Thr4160ProfsTer8]}$ $S_{B\text{-}I}$
I:2 age 62, M_O O_O G_{AD} $E_{G\text{-}PYGM[p.Arg50X\ hetero]}$ $S_{A\text{-}I}$
II:1 → age 34, $M_{H+D\ (>sCK)}$ O_{H+M} G_{AD} $E_{G\text{-}PYGM[p.Arg50X\ hetero]\ +\ TTN[p.Thr4160ProfsTer8]}$ $S_{C\text{-}II}$

Pedigree

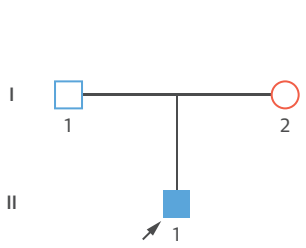

II:1 sCK levels: age 11 to 34

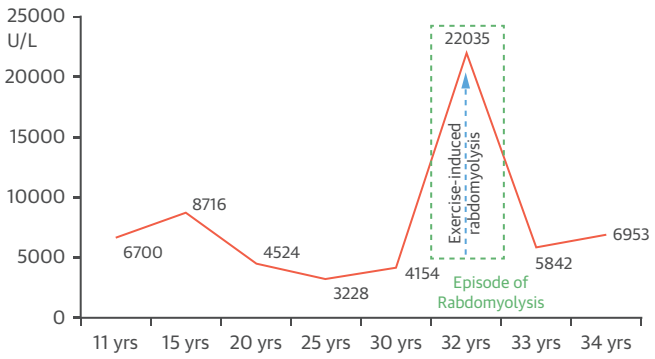

II:1 → Clinical history

Infancy, cardiac murmur, 2D-TTE BAV diagnosis
age 11, **>sCK (6700 U/L)** incidentally found before tonsillectomy
age 15, skeletal muscle biopsy. Myophosphorylase enzymatic activity 1.9 nmol/min/mg (RR: 65-240 nmol/min/mg). Diagnosis of McArdle disease
age 27, LV maximum thickness 12mm, LVEDD 60mm, LVEF 50%. Diagnosis of CMP
age 34, LVEDD 65mm, LVEF 45%, mild aortic regurgitation; Aortic Root Z-score = 2.22*

2D-TTE 4-Chambers - Diastole

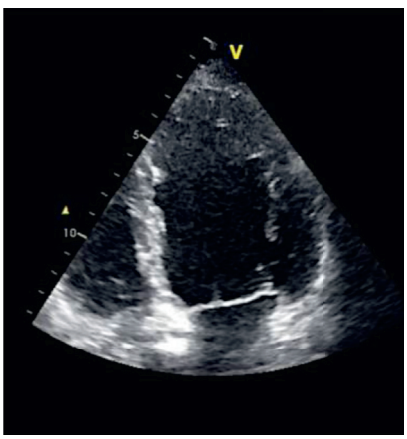

2D-TTE 4-Chambers - Systole

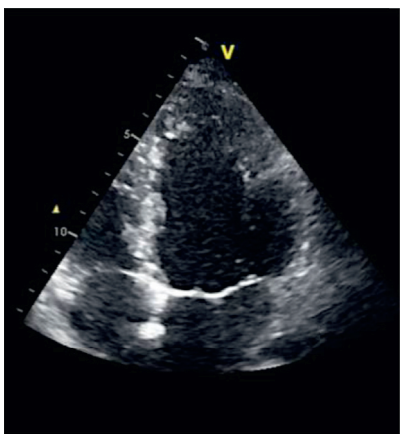

2D-TTE PSAX - BAV

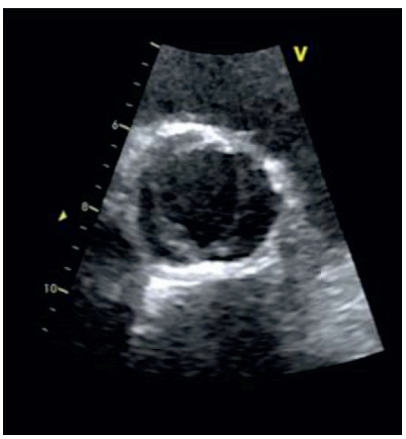

This patient demonstrated the typical GSD IV phenotype and nearly absent myophosphorylase enzymatic activity (1.9 nmol/min per mg). The cardiac phenotype is potentially explained by the paternally inherited truncation-predicting mutation in the *TTN* gene. BAV = bicuspid aortic valve; CMP = cardiomyopathy; RR = reference range; other abbreviations as in Figures 1 and 2.

gene *PYGM* encodes the myophosphorylase enzyme that initiates glycogen breakdown in skeletal muscle fibers (105). Mutations in *PYGM* reduce or abolish enzyme activity in the muscle. Clinical diagnosis can be suspected on the basis of exercise-related symptoms, baseline hyperCKemia, and myoglobinuria (>50%) and is confirmed by dosages at the level of myophosphorylase activity and by genetic testing. Genetic diagnosis is facilitated by the association of the disease with recurrent mutations, for example, p.(Arg50Ter) in up to 85% of patients, followed by p.(Gly205Ser) in up to 10% of cases in non-Asian populations, and p.(Phe710del) in the Japanese population (105). Patients are either homozygous or

double heterozygous carriers. When the second mutation is not found, the enzymatic deficiency confirms the diagnosis (105). Cardiomyopathy is uncommon; when present, it manifests with mild HCM with possible evolution through LV dilation. Unique cases of severe obstructive HCM (106) or mild HCM with DCM-like evolution may suggest a second mutation potentially contributing to the cardiomyopathy (**Figure 6**).

HCM can be the presenting trait in the AR GSD type XV that is caused by mutations in *GYG1* with deficiency of glycosyltransferase glycogenin 1 (107). This enzyme is the first activator of glycogen synthesis and catalyzes the formation of a short glucose polymer. The muscular isoform glycogenin1 is encoded by the *GYG1* gene and is expressed in tissues other than skeletal muscle; the liver isoform glycogenin2 encoded by the *GYG2* gene is also expressed in cardiac but not in skeletal muscle. To date, most reported cases have demonstrated polyglucosan body myopathy without cardiac involvement (98).

FATTY ACID OXIDATION DISORDERS: MYOPATHIES AND CARDIOMYOPATHIES. These AR diseases are classified on the basis of whether the defect involves the plasma membrane function or transport or the long-, medium-, and short-chain fatty acid β-oxidation. Both heart and skeletal muscle may be variably involved. For example, VLCADD (deficiency of very-long-chain acyl-coenzyme A [acyl-CoA] dehydrogenase) can clinically manifest with 3 phenotypes: the severe early-onset cardiac and multiorgan failure form; the hepatic or hypoketotic hypoglycemic form without cardiomyopathy; and the later-onset episodic myopathic form with skeletal muscle symptoms and exercise-induced intermittent rhabdomyolysis. Diagnosis is confirmed on the basis of abnormal acylcarnitine biochemical analysis (108) and/or biallelic mutations in the *ACADVL* gene (**Figure 7**). HyperCKemia is common. The cardiac phenotype is HCM or HCM with DCM-like evolution and complications such as arrhythmias and pericardial effusion. Early supportive care and a low-fat diet supplemented by medium-chain triglycerides and triheptanoin can improve the cardiomyopathy and myopathy. Cardiomyopathy and arrhythmias are uncommon in these patients (109), but ventricular arrhythmias and AV block (AVB) have been reported (108). The heart also can be involved in the 3 forms of AR carnitine palmitoyltransferase II deficiency, including: 1) the lethal neonatal form; 2) the severe infantile hepatocardiomuscular form; and 3) the later-onset myopathic form (110). Finally, LV hypertrophy and sudden death can also occur in multiple acyl-CoA dehydrogenase deficiency (111).

HYPERCKEMIA IN SARCOMERIC HCM: EXAMPLE OF THE *MYH7* GENE. Mild hyperCKemia can occur in patients with HCM, caused by sarcomeric proteins such as the myosin heavy chain 7 (*MYH7*) gene (112). The protein is expressed in both cardiac myocytes and type I skeletal muscle fibers, but overt myopathy/dystrophy is rare in *MYH7*-HCM patients. When hyperCKemia segregates with the HCM but skeletal muscle signs and symptoms are absent, the finding remains a descriptive trait that does not influence clinical decisions.

RESTRICTIVE PHENOTYPES

Diastolic dysfunction is common in HCM phenotypes and is one of the diagnostic markers of RCM when associated with the presence of normal or reduced diastolic volumes of one or both ventricles, normal or reduced systolic volumes, normal ventricular wall thickness, and enlarged atria (113). Restrictive physiology recurs in hearts from patients with myofibrillar myopathies (MFM) and in systemic diseases such as amyloidosis, in which, however, the skeletal muscle involvement is uncommon.

MYOFIBRILLAR MYOPATHIES WITH RCM. This group of myopathies may manifest with a restrictive pattern and conduction defects in association with hyperCKemia. The disease marker is the abnormal accumulation of intrasarcoplasmic proteins with vacuoles and disorganization of the myofibrillar network at the level of the Z-disks. In fact, disruption of the different proteins interconnecting Z-bands causes accumulation of degradation products that are observed in skeletal muscle and endomyocardial biopsies (114). MFM are clinically characterized by slowly progressive weakness of both the proximal and distal skeletal muscles (80%). Additional symptoms include sensory defects, skeletal muscle stiffness, cramps and aching. Cardiomyopathy is reported in approximately one-third of patients (114). The disease genes include *DES*, *CRYAB*, *LDB3/ZASP*, *MYOT*, *FLNC*, *BAG3*, and rarely *KY* and *PYROXD1*. In clinical reports of MFM with detailed description of cardiac phenotypes, a distinct proportion of cardiomyopathy presents as restrictive cardiomyopathy (RCM) and bears poor clinical prognosis (Online Table 5A). New entries include *FHL1* and *TTN* MFMs (115,116) in which the cardiac phenotype is described as HCM or HCM with diastolic dysfunction or "heart disease" or an unclassifiable cardiomyopathy. In patients with *FHL1* mutations, the cardiac phenotype

FIGURE 7 Autosomal Recessive Deficiency of Very-Long-Chain Acyl-CoA Dehydrogenase Complex Genotype

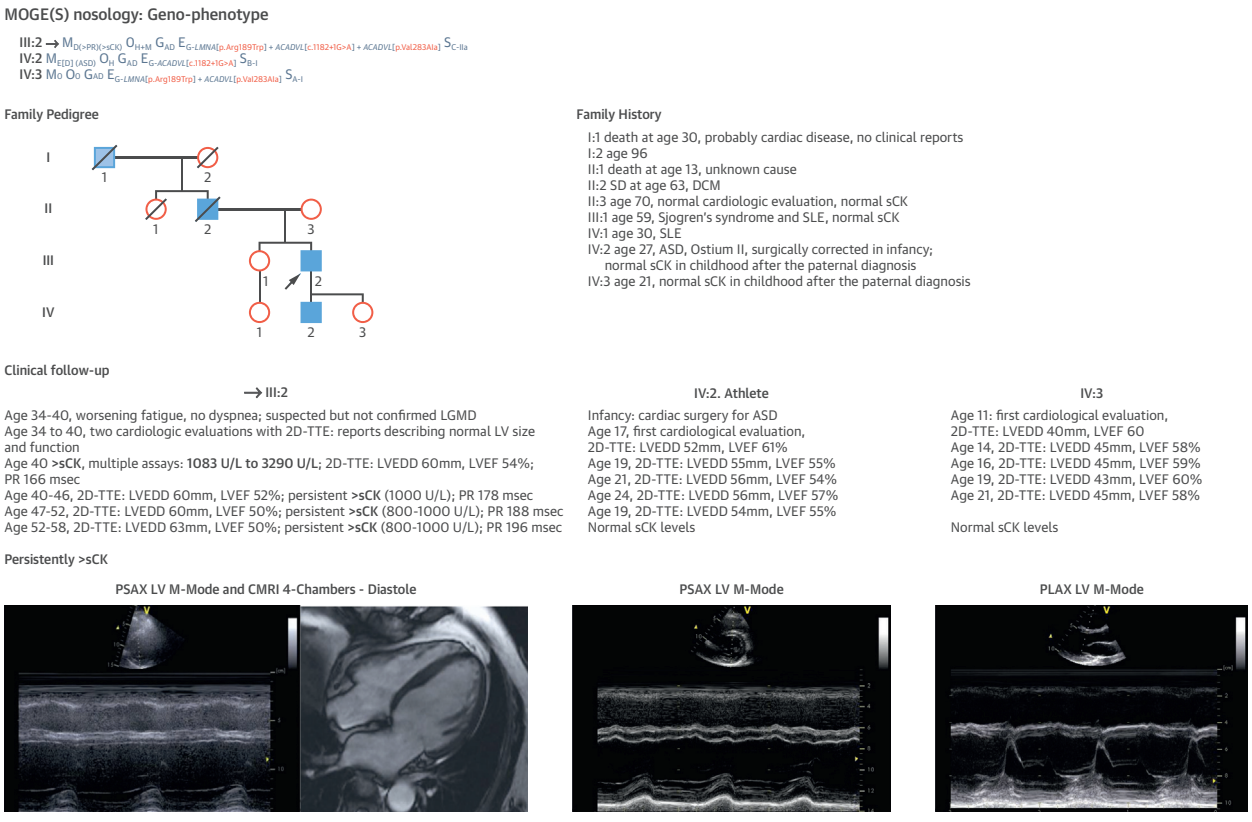

The effects of the mutations in the 2 genes are difficult to dissect in the proband (III:2). The natural history of the disease will be better described with follow-up of the young son (IV:3), who carries only 1 mutation in the *ACADVL* gene and the *LMNA* mutation. ASD = atrial-septal defect; SD = sudden death; SLE = systemic lupus erythematosus; other abbreviations as in Figures 1 and 3.

often reveals LV hypertrophy with atrial dilation and RCM (117) and may be present without myopathy.

A unique clinicopathologic phenotype is represented by the highly malignant, restrictive cardiodesminopathy with AVB and intramyocyte accumulation of osmiophilic granulophilamentous, desmin-immunoreactive material. The disease occurs early and demonstrates irreversible evolution through end-stage HF at a young age, requiring HTx (118) (**Figure 8**). Although the RCM can be the first clinical manifestation of the disease, the skeletal muscle is always structurally affected, even in the absence of clinically overt myopathy (50,118–123). When the skeletal muscle is minimally involved, HTx is feasible and demonstrates the same outcome as in patients not affected by *DES* mutations. Pertaining to cardiac involvement, DCM and arrhythmogenic right ventricular cardiomyopathy have been reported in association with *DES* mutations, but there is little evidence of an association with the typical pathological features of MFM, also due to the lack of availability of myocardial pathologic studies.

RCM phenotype also characterizes the cardiomyopathy in *BAG3*-opathies with MFM. Carriers of the p.(Pro209Leu) mutation in the *BAG3* gene develop early RCM (124–127) with typical intrasarcoplasmic inclusion bodies (127,128). HTx is the only treatment option for the end-stage myocardial disease, although this can be limited by the severity of systemic involvement. The description of the cardiac phenotypes is less clear in other MFMs. When MFM is associated with cataracts or hypokinetic cardiomyopathy with restrictive filling pattern, the MFM can be caused by defects in the *CRYAB* gene (alpha-B crystallinopathies) (129,130). Cardiomyopathy was described in 2 of 5 affected members of a family with multisystemic disease, including MFM, cataracts, dysphagia, dysphonia, and respiratory

FIGURE 8 Cardiodesminopathy and Myopathy

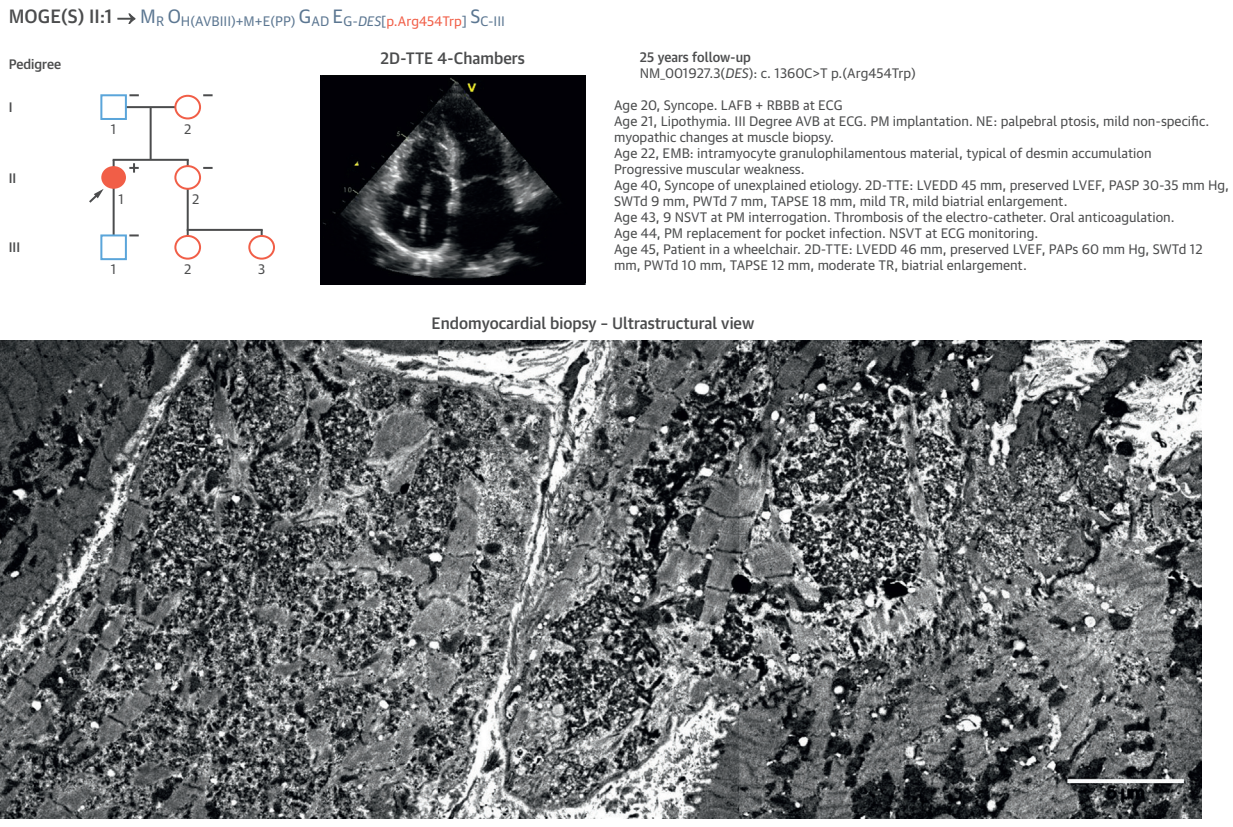

Myofibrillar myopathy caused by a *DES* mutation: the triad (RCM, AVB, myopathy) is characteristic, but the muscle involvement is prominent, and the patient's ambulation is now severely impaired. NE = neurologic examination; PASP = pulmonary artery systolic pressure; RCM = restrictive cardiomyopathy; TAPSE = tricuspid annular plain systolic excursion; TR = tricuspid regurgitation; other abbreviations as in Figures 1, 2, and 3.

failure (130). Mutations in the *LDB3* gene, which encodes a skeletal actin binding protein, have been associated with DCM and LV noncompaction (LVNC); however, in MFM patients, DCM is rare or absent (131,132). The cardiac involvement is often reported as "cardiomyopathy" with or without AV block in MFM cases and series (47,133). Finally, RCM has been described in patients with *FLNC* mutations (134).

OVERLAPPING MUSCLE PHENOTYPES: THE CASE OF THE *FHL1* GENE. Mutations in the *FHL1* gene may cause isolated cardiomyopathy (no myopathy) (117,135), reduction body myopathy, scapuloperoneal myopathy, X-linked myopathy with postural muscle atrophy, rigid spine syndrome, and EDMD (136). The inheritance is XL dominant or recessive. The cardiac phenotype is mild HCM but with variable descriptions of atrial dilation and diastolic dysfunction. Alternatively, patients may demonstrate arrhythmias (Online Table 5B). Systematic cardiac evaluation and precise description of the cardiac phenotype could help cardiologists in better supporting neurologists who care for most of these patients (8). The recurrent finding of reduction bodies suggests intramyocyte accumulation of myofibrillar degradation products similar to MFM.

AMYLOID MYOPATHY. Amyloid myopathy can occur in systemic amyloidosis (137-139) in which cardiac involvement typically manifests with a restrictive phenotype. In contrast, "isolated" amyloid myopathy is a rare, recently described entity (140) that can be subgrouped into 2 pathologically distinct intracellular and extracellular forms; the former includes the sporadic and acquired inclusion body myopathy, affecting patients over 50 years of age (141) or hereditary inclusion body myopathies (140); whereas the latter includes isolated amyloid myopathy due to mutations in the anoctamin-5 (*ANO5*) gene, which are more common, and the dysferlin (*DYSF*) gene,

respectively (140,142,143). Mutations in the *DYSF* and *ANO5* genes have also been associated with cardiomyopathy (143,144). The cardiac phenotype is still poorly described in cardiomuscular anoctaminopathies and dysferlinopathies; available data report an increased risk of ventricular arrhythmia and possible diastolic dysfunction (144,145).

LEFT VENTRICULAR NONCOMPACTION

The term LVNC describes a ventricular wall anatomy with prominent LV trabeculae, a thin compacted layer, and deep intertrabecular recesses. This definition usually includes the proportion between the trabecular and compacted layers of the LV (≥2) (146). The definition does not include functional implications, which are manifested when LVNC is associated with dilated, hypertrophic, or restrictive cardiomyopathies. LVNC has been described in association with many different heritable muscle diseases (dystrophinopathies, myotonic dystrophies, LGMD, EDMD, Friedreich's ataxia, metabolic diseases, both mitochondrial, glycogenosis, fatty acid oxidation disorders) as well as congenital heart defects, genetic syndromes, and cardiomyopathies. In addition, LVNC has also been described in pregnant women, athletes, patients with renal and hematological diseases, hypertensive patients, and in apparently healthy subjects, all with normal LV function, suggesting that it can represent a morphological expression of different underlying conditions rather than a distinct cardiomyopathy (147,148). The possible prognostic role is also debated in the general population (149), whereas in DMD/BMD, the presence of LVNC seems to be significantly associated with a rapid deterioration in LV function and higher mortality (150).

XLR BARTH SYNDROME. XLR Barth syndrome (BTHS) is the paradigmatic example of an LVNC dilated, hypokinetic cardiomyopathy associated with early nonprogressive, hypotonic skeletal myopathy involving proximal muscles with developmental motor delay (151,152). Biomarkers include methylglutaconic aciduria and increased plasma 3-methylglutaconic acid, and neutropenia (neutrophil count ranging from <500 to 1,500 neutrophils/μl) accompanied by substantial monocytosis that may mitigate the risk and severity of infection. Other traits can include oral aphtae, dysmorphic facial traits, and selective learning difficulties (>50% of cases). The traits that characterize BTHS can be present in variable combinations and severity in the different patients in whom the cardiomyopathy occurs in >90% of cases. Carrier mothers frequently report miscarriages of male fetuses (151). BTHS is included in mitochondrial disorders. In fact, the disease gene (*TAZ*) encodes the protein Tafazzin, which is located on the inner mitochondrial membrane. The protein catalyzes reaction of the acyl chains of immature cardiolipin to mature cardiolipin that is essential for high-energy-consuming tissues such as myocardial tissue. Early-onset BTHS DCM in children carries a poor prognosis and can be unrecognized (153) or manifest with acute heart failure (154). Severity of the cardiac phenotype is variable. HTx is a possible treatment option (155), carefully considering the risk of post-HTx infections in neutropenic patients. Patients who survive the first 5 years of life appear to have a good prognosis (156), especially when appropriately cared for in multidisciplinary settings (157). Monitoring is based on the systematic control of cardiac and noncardiac abnormalities. A recent national cohort study reported that modern management of heart failure and prevention of infection in infancy may improve the survival of patients with BTHS without the need for HTx (158).

RHYTHM DISORDERS AND MYOPATHIES

Conduction diseases and arrhythmias are common in skeletal muscle diseases, including those that do not cause cardiomyopathies. Some forms of muscular dystrophy are typically associated with conduction defects and carry a high arrhythmogenic risk. Patients are referred to the cardiologist for conduction defects, arrhythmias, or syncope. Alternatively, patients can be referred for the assessment of simple ECG changes such as right bundle branch block, a recurrent finding in fascio-scapulohumeral MD that is the third most common MD characterized by little cardiac involvement (159). Life-threatening ventricular arrhythmias and sudden death can be the first clinical manifestations of the myotonic dystrophies and skeletal muscle channelopathies.

MYOTONIC DYSTROPHIES. Myotonic dystrophy type 1 (DM1) and 2 (DM2) are multisystemic diseases clinically characterized by myotonia, progressive skeletal muscle weakness, conduction defects, and central nervous system involvement. Family pedigree and clinical family screening may demonstrate the phenomenon of anticipation, that is, worsening of the disease phenotype through subsequent generations. In offspring of affected parents, the phenotype manifests earlier than in the affected parent and grandparent (160).

DM1. The unstable CTG repeat expansion in the *DMPK* gene increases from one generation to the

FIGURE 9 Anoctaminopathy, the Early Cardiac Phenotype Is Hypertrophic

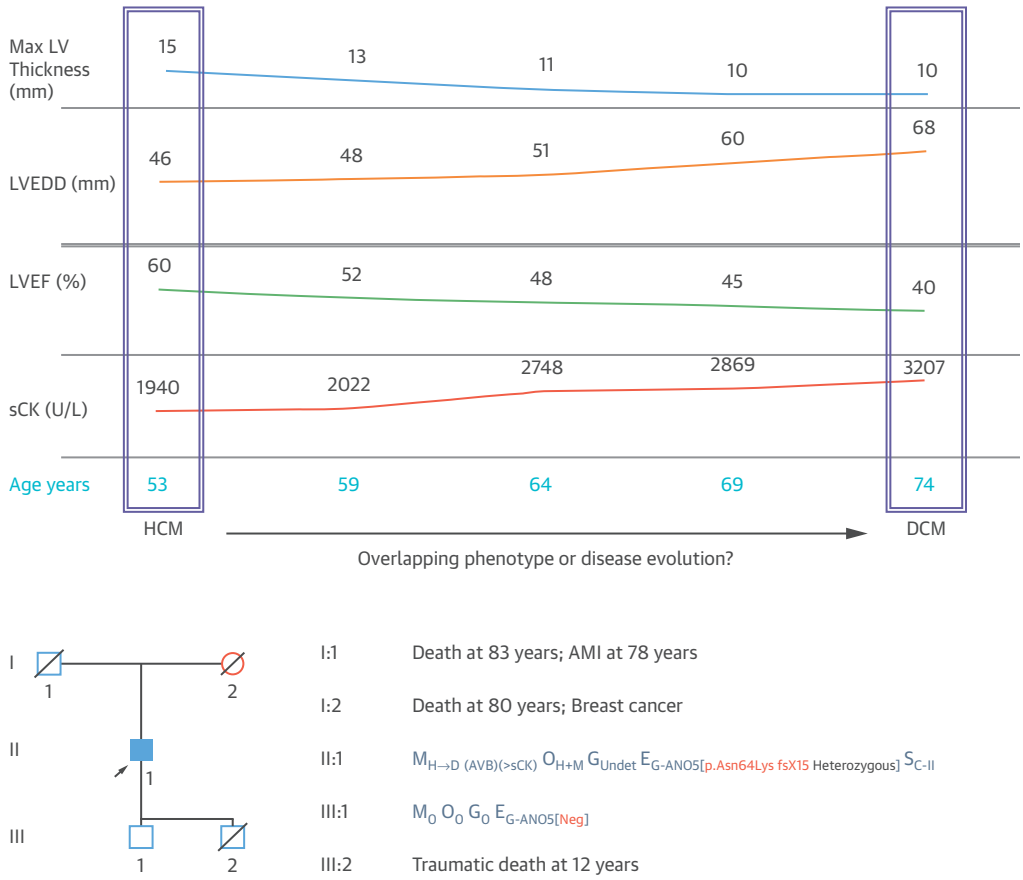

Long-term evolution of symmetrical nonobstructive HCM diagnosed in an adult (53 years of age) associated with hyperCKemia and a non-characterized, mild thigh muscle myopathy. Two muscular biopsies at age 61 described nonspecific myopathic changes. Cardiomyopathy gene and mtDNA testing returned negative results. Genetic analysis identified a heterozygous truncation-predicting mutation in the *ANO5* gene. Anoctaminopathies are autosomal recessive dystrophies, with the exception of gnathodiaphyseal dysplasia (not corresponding to the phenotype of our proband II:1). Therefore, the genetic diagnosis remains uncertain. The cardiac phenotype was HCM at onset and DCM at late follow-up. mtDNA = mitochondrial DNA; all other abbreviations are as in **Figures 1 and 2**.

next, and the extent of the expansion is associated with the severity of the phenotype (160). Therefore, DM1 is divided into 5 groups according to the most recent criteria of the International Myotonic Dystrophy Consortium (161): group 1 is congenital (present at birth, <1 year) with CGT length >1,000, severe hypotonia, feeding difficulties, respiratory insufficiency, and cardiorespiratory complications; group 2 includes childhood-onset (1 to 10 years of age) with 50 to 1,000 CGT repeat expansions, myotonia, and cardiac conduction defects; group 3 includes juvenile-onset (11 to 20 years of age) with 50 to 1,000 CGT repeat expansions, absence of or minor motor and cardiac involvement that can appear later in life; group 4 consists of adult-onset (20 to 40 years of age) with 50 to 1,000 CGT repeat expansions, myotonia, cataracts, conduction defects, insulin resistance, and respiratory failure; and group 5 consists of late-onset/asymptomatic (>40 years of age) with 50 to 100 CGT repeat expansions, cataracts, and mild myotonia. The premutation (38 to 49 CGT repeat expansions) does not have clinical manifestations. Conduction defects are the most common and well-recognized cardiac traits of the disease (162). Cardiomyopathy is possible but rare and shows variable phenotype. In contrast, the risk of sudden death is high and should be carefully considered because ventricular arrhythmias or complete heart block can occur in the early stages of disease (163). In a large cohort of DM1 patients followed for 10 years, the overall mortality rate was

CENTRAL ILLUSTRATION **Predominant Cardiovascular Phenotypes in the Most Commonly Inherited Muscle Diseases With Cardiac Involvement**

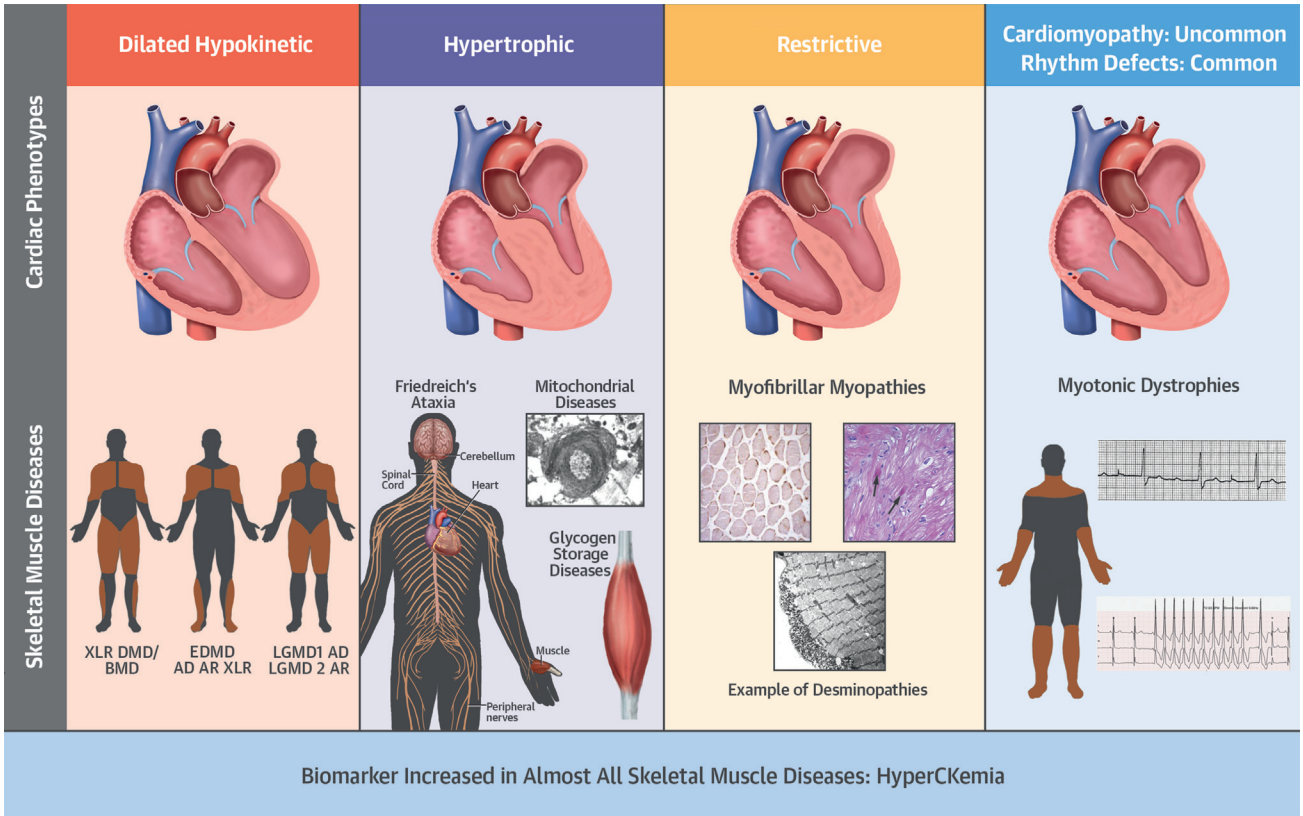

Arbustini, E. et al. J Am Coll Cardiol. 2018;72(20):2485–506.

Cardiac phenotypes can largely overlap, and the ones represented here constitute those most frequently observed in the given hereditary muscle diseases.
AD = autosomal dominant; AR = autosomal recessive; BMD = Becker muscular dystrophy; DMD = Duchenne muscular dystrophy; EDMD = Emery-Dreifuss muscular dystrophies; LGMD = limb girdle muscular dystrophies; XLR = X-linked recessive.

20%. Ages at death ranged from 44.7 years for patients with the childhood phenotype to 63.5 years for patients with the mild late-onset type ($p = 0.005$) (164). Recent studies showed that DM1 patients with small numbers of CTG expansions are at increased risk of cardiac events similar to DM1 patients with larger number of CTG expansions. Therefore, cardiac follow-up should not differ between patients with small triplet expansions and those with large triplet expansions (165).

DM2. In DM2 (or proximal myotonic myopathy [PROMM]), the genetic defect consists of a CCTG repeat expansion (75 to 11,000 repeats) in intron 1 of the *CNBP/ZNF9* gene. DM2 patients complain of skeletal muscle pain and weakness, myotonia (from 60% [166] to 85% [167]), hypogonadism (male patients), cardiac rhythm disorders, diabetes, and early cataracts. Cardiac conduction defects range from 20% to 36% (168,169). Atrial fibrillation has been reported to occur in 16% of cases, LV systolic dysfunction in 10% of cases, and HF in 16% of patients (170). DCM is not common but when present can manifest with severe phenotype (171). Rare cases of sudden death have been reported in DM2 patients (172).

In both the aforementioned contexts, many patients referred to cardiologists are genetically characterized. Genetic testing has been feasible for decades with nearly 100% diagnostic yield. Overall, cardiac involvement occurs in up to 90% of DM1 patients and is characterized by conduction abnormalities with arrhythmias. AVB and need for pacemaker implantation are the most common indications for cardiology consultation. One-third of these patients die suddenly; the electrophysiology study assesses the indications for dual chamber pacemaker or ICD (173).

HERITABLE SKELETAL MUSCLE CHANNELOPATHIES. Skeletal muscle channelopathies have recently come to the attention of cardiologists because they are a possible cause of malignant ventricular arrhythmias and sudden death. They are rare genetic neuromuscular disorders (1:100,000 prevalence) (174) that include the nondystrophic myotonias (175) and primary periodic paralysis (176). Known disease-causing genes are *CLCN1* (myotonia congenita), *SCN4A* (paramyotonia congenita, hyperkalemic, and hypokalemic periodic paralysis type 2), *CACNA1S7* (hypokalemic periodic paralysis type 1), and *KCNJ28* (Andersen-Tawil syndrome) (177). Clinical manifestations include myotonia, skeletal muscle hypertrophy, proximal weakness, swallowing difficulties, and periodic paralysis (177). Cardiac arrhythmias may complicate muscle channelopathies and are potentially life-threatening (178). QT prolongation may occur in Andersen-Tawil syndrome; the risk of symptomatic cardiac involvement is high (sudden death in 2 of 15 cases and ICD implantation in 40%) (179). In a large sudden infant death syndrome cohort, 1.4% of infants (4 of 278) had a rare functionally disruptive *SCN4A* variant compared with none (0%) in 729 ethnically matched controls ($p = 0.0057$) (180).

STUDY LIMITATIONS

Because of the vastness and complexity of hereditary muscle diseases, we deemed it useful to select the groups of myopathies most frequently associated with clinically relevant cardiac phenotypes, limiting the comprehensive nature of the description but adopting the diagnostic strategy used in clinical cardiology practice. In addition, the epidemiology of the different cardiac phenotypes in genetic myopathies is influenced by the timing of diagnosis (when patients with myopathy are referred to cardiovascular care) as well as by the precision of their description (**Figure 9**). Finally, 2 genetic diseases can coexist in the same patient as shown in the example illustrated in Online Figure 1 in which the infantile XLR epileptic encephalomyopathy is caused by the *ARX* gene mutation, while the HCM is caused by the *TNNT2* gene mutation.

CONCLUSIONS

Inherited muscle disorders are far more common than generally believed. As expected, they are diagnosed and treated by neurologists. However, the heart is commonly involved in most cases (Online Table 6) and requires comprehensive cardiology care. Cardiac phenotypes (cardiomyopathies and rhythms disorders) can be the first or predominant manifestations. The spectrum of cardiac manifestations in neuromuscular diseases is wide. Related cardiac phenotypes may be dilated, hypertrophic, or restrictive, with potential overlap. Rhythm disorders occur in cardiomyopathies or present as isolated manifestations, especially in myotonic dystrophies and muscle channelopathies (**Central Illustration**). Simple biomarkers (e.g., serum creatine kinase, lactic acidemia) should be systematically tested because they can provide preliminary clues for exploring skeletal muscle disease in patients with cardiomyopathies or rhythm disorders. Potentially fatal arrhythmias and end-stage heart failure are terminal events. Cardiologists may be at the front line of complex diagnostic pathways and demanding clinical emergencies (e.g., resuscitated cardiac arrest, indications for HTx (Online Table 7) in the context of systemic diseases). Continuous cardiovascular care is therefore necessary in a large proportion of patients with skeletal muscle disorders and cardiac involvement.

ACKNOWLEDGMENT The authors thank Monica Concardi for excellent and continuous technical assistance with pathology studies.

ADDRESS FOR CORRESPONDENCE: Dr. Eloisa Arbustini, Centre for Inherited Cardiovascular Diseases, IRCCS Foundation, University Hospital Policlinico San Matteo, Piazzale Golgi 19, 27100 Pavia, Italy. E-mail: e.arbustini@smatteo.pv.it.

REFERENCES

1. Mathis S, Tazir M, Magy L, et al. History and current difficulties in classifying inherited myopathies and muscular dystrophies. J Neurol Sci 2018;384:50–4.

2. Malfatti E, Romero NB. Diseases of the skeletal muscle. Handb Clin Neurol 2017:429–51.

3. Finsterer J, Stöllberger C, Wahbi K. Cardiomyopathy in neurological disorders. Cardiovasc Pathol 2013;22:389–400.

4. Groh WJ. Arrhythmias in the muscular dystrophies. Heart Rhythm 2012;9:1890–5.

5. McNally EM, Pytel P. Muscle diseases: the muscular dystrophies. Annu Rev Pathol 2007;2:87–109.

6. Tawil R, Kissel JT, Heatwole C, et al. Evidence-based guideline summary: evaluation, diagnosis, and management of facioscapulohumeral muscular dystrophy: report of the Guideline Development, Dissemination, and Implementation Subcommittee of the American Academy of Neurology and the Practice Issues Review Panel of the American Association of Neuromuscular & Electrodiagnostic Medicine. Neurology 2015;85:357–64.

7. Feingold B, Mahle WT, Auerbach S, et al. Management of cardiac involvement associated with neuromuscular diseases: a scientific statement from the AHA. Circulation 2017;136:e200–31.

8. Arbustini E, Narula N, Tavazzi L, et al. The MOGE(S) classification of cardiomyopathy for clinicians. J Am Coll Cardiol 2014;64:304–18.

9. Sommerville RB, Vincenti MG, Winborn K, et al. Diagnosis and management of adult hereditary cardioneuromuscular disorders: a model for the multidisciplinary care of complex genetic disorders. Trends Cardiovasc Med 2017;27:51–8.

10. Bushby K, Finkel R, Birnkrant DJ, et al. Diagnosis and management of Duchenne muscular dystrophy, part 1: diagnosis, and pharmacological and psychosocial management. Lancet Neurol 2010;9:77–93.

11. Bushby K, Thambyayah M, Gardner-Medwin D. Prevalence and incidence of Becker muscular dystrophy. Lancet 1991;337:1022–4.

12. Muntoni F, Torelli S, Ferlini A. Dystrophin and mutations: one gene, several proteins, multiple phenotypes. Lancet Neurol 2003;2:731–40.

13. McNally EM, Kaltman JR, Benson DW, et al. Contemporary cardiac issues in Duchenne muscular dystrophy. Circulation 2015;131:1590–8.

14. Thrush PT, Allen HD, Viollet L, et al. Re-examination of the electrocardiogram in boys with Duchenne muscular dystrophy and correlation with its dilated cardiomyopathy. Am J Cardiol 2009;103:262–5.

15. Chiang DY, Allen HD, Kim JJ, et al. Relation of cardiac dysfunction to rhythm abnormalities in patients with Duchenne or Becker muscular dystrophies. Am J Cardiol 2016;117:1349–54.

16. Silva MC, Magalhães TA, Meira ZMA, et al. Myocardial fibrosis progression in Duchenne and Becker muscular dystrophy: a randomized clinical trial. JAMA Cardiol 2017;2:190–9.

17. Nigro G, Comi L, Politano L, et al. The incidence and evolution of cardiomyopathy in Duchenne muscular dystrophy. Int J Cardiol 1990;26:271–7.

18. Connuck D, Sleeper L, Colan S, et al., for the Pediatric Cardiomyopathy Registry Study Group. Characteristics and outcomes of cardiomyopathy in children with Duchenne or Becker muscular dystrophy: a comparative study from the pediatric cardiomyopathy registry. Am Heart J 2008;155:998–1005.

19. Duboc D, Meune C, Lerebours G, et al. Effect of perindopril on the onset and progression of left ventricular dysfunction in Duchenne muscular dystrophy. J Am Coll Cardiol 2005;45:855–7.

20. Amodeo A, Adorisio R. Left ventricular assist device in Duchenne cardiomyopathy: can we change the natural history of cardiac disease? Int J Cardiol 2012;161:e43.

21. Ryder S, Leadley R, Armstrong N, et al. The burden, epidemiology, costs and treatment for Duchenne muscular dystrophy: an evidence review. Orphanet J Rare Dis 2017;12:79.

22. Jefferies JL, Eidem BW, Belmont JW, et al. Genetic predictors and remodeling of dilated cardiomyopathy in muscular dystrophy. Circulation 2005;112:2799–804.

23. Saito M, Kawai H, Akaike M, et al. Cardiac dysfunction with Becker muscular dystrophy. Am Heart J 1996;132:642–7.

24. Hoogerwaard E, de Voogt WG, Wilde AA, et al. Evolution of cardiac abnormalities in Becker muscular dystrophy over a 13-year period. J Neurol 1997;244:657–63.

25. Diegoli M, Grasso M, Favalli V, et al. Diagnostic work-up and risk stratification in X-linked dilated cardiomyopathies caused by dystrophin defects. J Am Coll Cardiol 2011;58:925–34.

26. Yancy CW, Jessup M, Bozkurt B, et al. 2013 ACCF/AHA guideline for the management of heart failure: a report of the American College of Cardiology Foundation/American Heart Association Task Force on Practice Guidelines. J Am Coll Cardiol 2013;62:e147–239.

27. Towbin JA, Hejtmancik JF, Brink P, et al. X-linked dilated cardiomyopathy. Molecular genetic evidence of linkage to the Duchenne muscular dystrophy (dystrophin) gene at the Xp21 locus. Circulation 1993;87:1854–65.

28. Arbustini E, Diegoli M, Morbini P, et al. Prevalence and characteristics of dystrophin defects in adult male patients with dilated cardiomyopathy. J Am Coll Cardiol 2000;35:1760–8.

29. Nakamura A. X-linked dilated cardiomyopathy: a cardiospecific phenotype of dystrophinopathy. Pharmaceuticals 2015;8:303–20.

30. Feng J, Yan J, Buzin CH, Towbin JA, et al. Mutations in the dystrophin gene are associated with sporadic dilated cardiomyopathy. Mol Genet Metab 2002;77:119–26.

31. Cohen N, Muntoni F. Multiple pathogenetic mechanisms in X linked dilated cardiomyopathy. Heart 2004;90:835–41.

32. Milasin J, Muntoni F, Severini G, et al. A point mutation in the 5′splice site of the dystrophin gene first intron responsible for X-linked dilated cardiomyopathy. Hum Mol Genet 1996;5:73–9.

33. Garry DJ. Dystrophin-deficient cardiomyopathy. J Am Coll Cardiol 2016;67:2533–46.

34. Papa AA, D'Ambrosio P, Petillo R, et al. Heart transplantation in patients with dystrophinopathic cardiomyopathy: review of the literature and personal series. Intractable Rare Dis Res 2017;6:95–101.

35. Narayanaswami P, Weiss M, Selcen D, et al. Evidence-based guideline summary: diagnosis and treatment of limb-girdle and distal dystrophies. Report of the Guideline Development Subcommittee of the American Academy of Neurology and the Practice Issues Review Panel of the American Association of Neuromuscular & Electrodiagnostic Medicine. Neurology 2014;83:1453–63.

36. Walton JN, Nattrass F. On the classification, natural history and treatment of the myopathies. Brain 1954;77:169–231.

37. Nigro V, Savarese M. Genetic basis of limb-girdle muscular dystrophies: the 2014 update. Acta Myol 2014;33:1.

38. Thompson R, Straub V. Limb-girdle muscular dystrophies—international collaborations for translational research. Nat Rev Neurol 2016;12:294.

39. Hicks D, Sarkozy A, Muelas N, et al. A founder mutation in Anoctamin 5 is a major cause of limb girdle muscular dystrophy. Brain 2010;134:171–82.

40. Norwood FL, Harling C, Chinnery PF, et al. Prevalence of genetic muscle disease in Northern England: in-depth analysis of a muscle clinic population. Brain 2009;132:3175–86.

41. Van der Kooi A, Barth P, Busch H, et al. The clinical spectrum of limb girdle muscular dystrophy A survey in the Netherlands. Brain 1996;119:1471–80.

42. Kirschner J, Lochmüller H. Sarcoglycanopathies. Handb Clin Neurol 2011:41–6.

43. Van Rijsingen IA, Arbustini E, Elliott PM, et al. Risk factors for malignant ventricular arrhythmias in lamin a/c mutation carriers: a European cohort study. J Am Coll Cardiol 2012;59:493–500.

44. Poppe M, Bourke J, Eagle M, et al. Cardiac and respiratory failure in limb-girdle muscular dystrophy 2I. Ann Neurol 2004;56:738–41.

45. Wattjes MP, Kley RA, Fischer D. Neuromuscular imaging in inherited muscle diseases. Eur Radiol 2010;20:2447–60.

46. Bushby K. Diagnosis and management of the limb girdle muscular dystrophies. Pract Neurol 2009;9:314–23.

47. Olivé M, Goldfarb LG, Shatunov A, et al. Myotilinopathy: refining the clinical and myopathological phenotype. Brain 2005;128:2315–26.

48. Captur G, Arbustini E, Bonne G, et al. Lamin and the heart. Heart 2018;104:468–79.

49. Gazzerro E, Bonetto A, Minetti C. Caveolinopathies: translational implications of caveolin-3 in skeletal and cardiac muscle disorders. Handb Clin Neurol 2011;101:135–42.

50. Arbustini E, Pasotti M, Pilotto A, et al. Desmin accumulation restrictive cardiomyopathy and atrioventricular block associated with desmin gene defects. Eur J Heart Fail 2006;8:477–83.

51. Hayashi T, Arimura T, Ueda K, et al. Identification and functional analysis of a caveolin-3 mutation associated with familial hypertrophic cardiomyopathy. Biochem Biophys Res Commun 2004;313:178–84.

52. Catteruccia M, Sanna T, Santorelli FM, et al. Rippling muscle disease and cardiomyopathy associated with a mutation in the CAV3 gene. Neuromuscul Disord 2009;19:779–83.

53. Bonne G, Leturcq F, Ben Yaou R. Emery-Dreifuss muscular dystrophy. In: Adam MP, Ardinger HH, Pagon RA, et al. editors. GeneReviews. University of Washington, Seattle; 1993-2018. Available at: http://www.ncbi.nlm.nih.gov/books/NBK1436. Accessed September 29, 2004.

54. Bione S, Maestrini E, Rivella S, et al. Identification of a novel X-linked gene responsible for Emery-Dreifuss muscular dystrophy. Nat Genet 1994;8:323.

55. Gueneau L, Bertrand AT, Jais JP, et al. Mutations of the FHL1 gene cause Emery-Dreifuss muscular dystrophy. Am J Hum Genet 2009;85:338–53.

56. Bonne G, Di Barletta MR, Varnous S, et al. Mutations in the gene encoding lamin A/C cause autosomal dominant Emery-Dreifuss muscular dystrophy. Nat Genet 1999;21:285–8.

57. Rajgor D, Shanahan CM. Nesprins: from the nuclear envelope and beyond. Expert Rev Mol Med 2013;15:e5.

58. Zhang Q, Bethmann C, Worth NF, et al. Nesprin-1 and-2 are involved in the pathogenesis of Emery-Dreifuss muscular dystrophy and are

critical for nuclear envelope integrity. Hum Mol Genet 2007;16:2816–33.

59. Liang WC, Mitsuhashi H, Keduka E, et al. TMEM43 mutations in Emery-Dreifuss muscular dystrophy-related myopathy. Ann Neurol 2011;69:1005–13.

60. Wiltshire KM, Hegele RA, Innes AM, Brownell AKW. Homozygous lamin A/C familial lipodystrophy R482Q mutation in autosomal recessive Emery-Dreifuss muscular dystrophy. Neuromuscul Disord 2013;23:265–8.

61. Meinke P, Nguyen TD, Wehnert MS. The LINC complex and human disease. Biochem Soc Trans 2011;39:1693–7.

62. Gossios TD, Lopes LR, Elliott PM. Left ventricular hypertrophy caused by a novel nonsense mutation in FHL1. Eur J Med Genet 2013;56:251–5.

63. San Román I, Navarro M, Martínez F, et al. Unclassifiable arrhythmic cardiomyopathy associated with Emery-Dreifuss caused by a mutation in FHL1. Clin Genet 2016;90:171–6.

64. Stoyanov N, Winterfield J, Varma N, et al. Atrial arrhythmias in the young: early onset atrial arrhythmias preceding a diagnosis of a primary muscular dystrophy. Europace 2014;16:1814–20.

65. Finsterer J, Stöllberger C, Sehnal E, et al. Dilated, arrhythmogenic cardiomyopathy in emery-dreifuss muscular dystrophy due to the emerin splice-site mutation c. 449+ 1G> A. Cardiology 2015;130:48–51.

66. Achmad C, Zada A, Affani M, et al. A novel de novo mutation in Lamin A/C gene in Emery-Dreifuss muscular dystrophy patient with atrial paralysis. J Atr Fibrillation 2017;9:1511.

67. Priori SG, Blomström-Lundqvist C, Mazzanti A, et al. 2015 ESC guidelines for the management of patients with ventricular arrhythmias and the prevention of sudden cardiac death. Eur Heart J 2015;36:2793–867.

68. Schulz JB, Boesch S, Bürk K, et al. Diagnosis and treatment of Friedreich ataxia: a European perspective. Nat Rev Neurol 2009;5:222–34.

69. Campuzano V, Montermini L, Moltò MD, et al. Friedreich's ataxia: autosomal recessive disease caused by an intronic GAA triplet repeat expansion. Science 1996;271:1423–7.

70. Michael S, Petrocine SV, Qian J, et al. Iron and iron-responsive proteins in the cardiomyopathy of Friedreich's ataxia. Cerebellum 2006;5:257–67.

71. Pandolfo M. Friedreich ataxia. Arch Neurol 2008;65:1296–303.

72. Payne RM. The heart in Friedreich's ataxia: basic findings and clinical implications. Prog Pediatr Cardiol 2011;31:103–9.

73. Reetz K, Dogan I, Costa AS, et al. Biological and clinical characteristics of the European Friedreich's Ataxia Consortium for Translational Studies (EFACTS) cohort: a cross-sectional analysis of baseline data. Lancet Neurol 2015;14:174–82.

74. Mottram PM, Delatycki MB, Donelan L, et al. Early changes in left ventricular long-axis function in Friedreich ataxia: relation with the FXN gene mutation and cardiac structural change. J Am Soc Echocardiogr 2011;24:782–9.

75. Weidemann F, Rummey C, Bijnens B, et al. The heart in Friedreich ataxia: definition of cardiomyopathy, disease severity, and correlation with neurological symptoms. Circulation 2012;125:1626–34.

76. Kipps A, Alexander M, Colan SD, et al. The longitudinal course of cardiomyopathy in Friedreich's ataxia during childhood. Pediatr Cardiol 2009;30:306–10.

77. Raman SV, Phatak K, Hoyle JC, et al. Impaired myocardial perfusion reserve and fibrosis in Friedreich ataxia: a mitochondrial cardiomyopathy with metabolic syndrome. Eur Heart J 2010;32:561–7.

78. Weidemann F, Liu D, Hu K, et al. The cardiomyopathy in Friedreich's ataxia—new biomarker for staging cardiac involvement. Int J Cardiol 2015;194:50–7.

79. Lagedrost SJ, Sutton MSJ, Cohen MS, et al. Idebenone in Friedreich ataxia cardiomyopathy—results from a 6-month phase III study (IONIA). Am Heart J 2011;161:639–45.

80. Elincx-Benizri S, Glik A, Merkel D, et al. Clinical experience with deferiprone treatment for Friedreich ataxia. J Child Neurol 2016;31:1036–40.

81. McCormick A, Shinnick J, Schadt K, et al. Cardiac transplantation in Friedreich Ataxia: Extended follow-up. J Neurol Sci 2017;375:471–3.

82. Molnar MJ, Kovacs GG. Mitochondrial diseases. Handb Clin Neurol 2017:147–55.

83. Gorman GS, Schaefer AM, Ng Y, et al. Prevalence of nuclear and mitochondrial DNA mutations related to adult mitochondrial disease. Ann Neurol 2015;77:753–9.

84. DiMauro S, Schon EA, Carelli V, Hirano M. The clinical maze of mitochondrial neurology. Nat Rev Neurol 2013;9:429–44.

85. Bates MG, Bourke JP, Giordano C, et al. Cardiac involvement in mitochondrial DNA disease: clinical spectrum, diagnosis, and management. Eur Heart J 2012;33:3023–33.

86. Hsu Y-HR, Yogasundaram H, Parajuli N, et al. MELAS syndrome and cardiomyopathy: linking mitochondrial function to heart failure pathogenesis. Heart Fail Rev 2016;21:103–16.

87. Rapezzi C, Arbustini E, Caforio AL, et al. Diagnostic work-up in cardiomyopathies: bridging the gap between clinical phenotypes and final diagnosis. A position statement from the ESC Working Group on Myocardial and Pericardial Diseases. Eur Heart J 2012;34:1448–58.

88. Meyers DE, Basha HI, Koenig MK. Mitochondrial cardiomyopathy: pathophysiology, diagnosis, and management. Tex Heart Inst J 2013;40:385–94.

89. DiMauro S, Hirano M. MELAS. In: Adam MP, Ardinger HH, Pagon RA, et al., editors. GeneReviews. Seattle: University of Washington, 2001: 1993–2018. Available at: http://www.ncbi.nlm.nih.gov/books/NBK1233/. Accessed: February 27, 2001.

90. Chinnery PF. Mitochondrial disorders overview. In: Adam MP, Ardinger HH, Pagon RA, et al., editors. GeneReviews. Seattle: University of Washington, 1993-2018. Available at: http://www.ncbi.nlm.nih.gov/books/NBK1224/. Accessed June 8, 2000.

91. Finsterer J. Left ventricular noncompaction and its cardiac and neurologic implications. Heart Fail Rev 2010;15:589–603.

92. Milone M, Wong LJ. Diagnosis of mitochondrial myopathies. Mol Genet Metab 2013;110:35–41.

93. Zaragoza MV, Brandon MC, Diegoli M, et al. Mitochondrial cardiomyopathies: how to identify candidate pathogenic mutations by mitochondrial DNA sequencing, MITOMASTER and phylogeny. Eur J Hum Genet 2011;19:200–7.

94. Ghezzi D, Baruffini E, Haack TB, et al. Mutations of the mitochondrial-tRNA modifier MTO1 cause hypertrophic cardiomyopathy and lactic acidosis. Am J Hum Genet 2012;90:1079–87.

95. O'Byrne JJ, Tarailo-Graovac M, Ghani A, et al. The genotypic and phenotypic spectrum of MTO1 deficiency. Mol Genet Metab 2018;123:28–42.

96. Hobson-Webb LD, Kishnani PS. How common is misdiagnosis in late-onset Pompe disease? Muscle Nerve 2012;45:301–2.

97. Chen MA, Weinstein DA. Glycogen storage diseases: diagnosis, treatment and outcome. Transl Sci Rare Dis 2016;1:45–72.

98. Laforêt P, Malfatti E, Vissing J. Update on new muscle glycogenosis. Curr Opin Neurol 2017;30:449–56.

99. Regalado J, Rodriguez M, Ferrer P. Infantile hypertrophic cardiomyopathy of glycogenosis type IX: isolated cardiac phosphorylase kinase deficiency. Pediatr Cardiol 1999;20:304–7.

100. De Castro M, Johnston J, Biesecker L. Determining the prevalence of McArdle disease from gene frequency by analysis of next-generation sequencing data. Genet Med 2015;17:1002–6.

101. Lukacs Z, Cobos PN, Wenninger S, et al. Prevalence of Pompe disease in 3,076 patients with hyperCKemia and limb-girdle muscular weakness. Neurology 2016;87:295–8.

102. Boentert M, Florian A, Dräger B, et al. Pattern and prognostic value of cardiac involvement in patients with late-onset Pompe disease: a comprehensive cardiovascular magnetic resonance approach. J Cardiovasc Magn Reson 2017;18:91.

103. Montagnese F, Granata F, Musumeci O, et al. Intracranial arterial abnormalities in patients with late onset Pompe disease (LOPD). J Inherit Metab Dis 2016;39:391–8.

104. D'souza RS, Levandowski C, Slavov D, et al. Danon disease: clinical features, evaluation, and management. Circ Heart Fail 2014;7:843–9.

105. Martín MA, Lucía A, Arenas J, et al. Glycogen storage disease type V. 2014. In: Adam MP, Ardinger HH, Pagon RA, et al., editors. GeneReviews. Seattle: University of Washington, 1993-2018. Available at, http://www.ncbi.nlm.nih.gov/books/NBK1344/. Accessed June 26, 2017.

106. Moustafa S, Patton DJ, Connelly MS. Unforeseen cardiac involvement in McArdle's disease. Heart Lung Circ 2013;22:769–71.

107. Hedberg-Oldfors C, Glamuzina E, Ruygrok P, et al. Cardiomyopathy as presenting sign of

glycogenin-1 deficiency-report of three cases and review of the literature. J Inherit Metab Dis 2017;40:139–49.

108. Miller MJ, Burrage LC, Gibson JB, et al. Recurrent ACADVL molecular findings in individuals with a positive newborn screen for very long chain acyl-coA dehydrogenase (VLCAD) deficiency in the United States. Mol Genet Metab 2015;116:139–45.

109. Pena LD, van Calcar SC, Hansen J, et al. Outcomes and genotype-phenotype correlations in 52 individuals with VLCAD deficiency diagnosed by NBS and enrolled in the IBEM-IS database. Mol Genet Metab 2016;118:272–81.

110. Vladutiu GD, Quackenbush EJ, Hainline BE, et al. Lethal neonatal and severe late infantile forms of carnitine palmitoyltransferase II deficiency associated with compound heterozygosity for different protein truncation mutations. J Pediatr 2002;141:734–6.

111. Singla M, Guzman G, Griffin AJ, et al. Cardiomyopathy in multiple acyl-CoA dehydrogenase deficiency. Pediatr Cardiol 2008;29:446–51.

112. Dabaj I, Carlier RY, Gómez-Andrés D, et al. Clinical and imaging hallmarks of the MYH7-related myopathy with severe axial involvement. Muscle Nerve 2018. Available at: https://doi.org/10.1002/mus.26137. Accessed June 18, 2018.

113. Arbustini E, Serio A, Favalli V, Dec GW, Palladini G, Narula J. Restrictive heart diseases. In: Fuster V, Harrington RAJN, editors. Hurst's the Hearth. 14th edition. New York: Mc Graw Hill, 2017:1482–508.

114. Adam M, Ardinger H, Pagon R, et al. Myofibrillar myopathy. In: Adam MP, Ardinger HH, Pagon RA, et al., editors. GeneReviews. Seattle: University of Washington, 1993-2018. Available at: https://www.ncbi.nlm.nih.gov/books/NBK1499/. Accessed: January 28, 2005.

115. Schoser B, Goebel H, Janisch I, et al. Consequences of mutations within the C terminus of the FHL1 gene. Neurology 2009;73:543–51.

116. Hedberg C, Melberg A, Dahlbom K, et al. Hereditary myopathy with early respiratory failure is caused by mutations in the titin FN3 119 domain. Brain 2013;137:e270.

117. Gallego-Delgado M, Delgado JF, Brossa-Loidi V, et al. Idiopathic restrictive cardiomyopathy is primarily a genetic disease. J Am Coll Cardiol 2016 28;67:3021–3.

118. Arbustini E, Morbini P, Grasso M, et al. Restrictive cardiomyopathy, atrioventricular block and mild to subclinical myopathy in patients with desmin-immunoreactive material deposits. J Am Coll Cardiol 1998;31:645–53.

119. Zhang J, Kumar A, Stalker H, et al. Clinical and molecular studies of a large family with desmin-associated restrictive cardiomyopathy. Clin Genet 2001;59:248–56.

120. Hager S, Mahrholdt H, Goldfarb LG, et al. Giant right atrium in the setting of desmin-related restrictive cardiomyopathy. Circulation 2006;113:e53–5.

121. Pruszczyk P, Kostera-Pruszczyk A, Shatunov A, et al. Restrictive cardiomyopathy with atrioventricular conduction block resulting from a desmin mutation. Int J Cardiol 2007;117:244–53.

122. Piñol-Ripoll G, Shatunov A, Cabello A, et al. Severe infantile-onset cardiomyopathy associated with a homozygous deletion in desmin. Neuromuscul Disord 2009;19:418–22.

123. Ojrzyńska N, Bilińska ZT, Franaszczyk M, et al. Restrictive cardiomyopathy due to novel desmin gene mutation. Kardiol Pol 2017;75:723.

124. Selcen D, Muntoni F, Burton BK, et al. Mutation in BAG3 causes severe dominant childhood muscular dystrophy. Ann Neurol 2009;65:83–9.

125. Odgerel Z, Sarkozy A, Lee HS, et al. Inheritance patterns and phenotypic features of myofibrillar myopathy associated with a BAG3 mutation. Neuromuscul Disord 2010;20:438–42.

126. Konersman CG, Bordini BJ, Scharer G, et al. BAG3 myofibrillar myopathy presenting with cardiomyopathy. Neuromuscul Disord 2015;25:418–22.

127. Schänzer A, Rupp S, Gräf S, et al. Dysregulated autophagy in restrictive cardiomyopathy due to Pro209Leu mutation in BAG3. Mol Genet Metab 2018;123:388–99.

128. Semmler AL, Sacconi S, Bach JE, et al. Unusual multisystemic involvement and a novel BAG3 mutation revealed by NGS screening in a large cohort of myofibrillar myopathies. Orphanet J Rare Dis 2014;9:121.

129. Brodehl A, Gaertner-Rommel A, Klauke B, et al. The novel αB-crystallin (CRYAB) mutation p.D109G causes restrictive cardiomyopathy. Hum Mut 2017;38:947–52.

130. Sacconi S, Féasson L, Antoine JC, et al. A novel CRYAB mutation resulting in multisystemic disease. Neuromuscul Disord 2012;22:66–72.

131. Zheng J, Chen S, Chen Y, et al. A novel mutation in the PDZ-like motif of ZASP causes distal ZASP-related myofibrillar myopathy. Neuropathology 2017;37:45–51.

132. Griggs R, Vihola A, Hackman P, et al. Zaspopathy in a large classic late-onset distal myopathy family. Brain 2007;130:1477–84.

133. Selcen D, Engel AG. Mutations in myotilin cause myofibrillar myopathy. Neurology 2004;62:1363–71.

134. Tucker NR, McLellan MA, Hu D, et al. Novel mutation in FLNC (filamin C) causes familial restrictive cardiomyopathy. Circ Cardiovasc Genet 2017 Dec;10(6). pii: e001780. Available at: https://doi.org/10.1161/CIRCGENETICS.117.001780. Accessed March 5, 2018.

135. Hartmannova H, Kubanek M, Sramko M, et al. Isolated X-linked hypertrophic cardiomyopathy caused by a novel mutation of the four-and-a-half LIM domain 1 gene. Circ Cardiovasc Genet 2013;6:543–51.

136. Cowling BS, Cottle DL, Wilding BR, et al. Four and a half LIM protein 1 gene mutations cause four distinct human myopathies: a comprehensive review of the clinical, histological and pathological features. Neuromuscul Disord 2011;21:237–51.

137. Muchtar E, Derudas D, Mauermann M, et al. Systemic immunoglobulin light chain amyloidosis-associated myopathy: presentation, diagnostic pitfalls, and outcome. Mayo Clin Proc 2016:1354–61.

138. Hutt DF, Gilbertson J, Quigley AM, et al. 99mTc-DPD scintigraphy as a novel imaging modality for identification of skeletal muscle amyloid deposition in light-chain amyloidosis. Amyloid 2016;23:134–5.

139. Carr A, Pelayo-Negro A, Jaunmuktane Z, et al. Transthyretin V122I amyloidosis with clinical and histological evidence of amyloid neuropathy and myopathy. Neuromuscul Disord 2015;25:511–5.

140. Liewluck T, Milone M. Characterization of isolated amyloid myopathy. Eur J Neurol 2017;24:1437–45.

141. Benveniste O, Stenzel W, Hilton-Jones D, et al. Amyloid deposits and inflammatory infiltrates in sporadic inclusion body myositis: the inflammatory egg comes before the degenerative chicken. Acta Neuropathol 2015;129:611–24.

142. Liewluck T, Winder T, Dimberg E, et al. ANO5 muscular dystrophy: clinical, pathological and molecular findings. Eur J Neurol 2013;20:1383–9.

143. Wahbi K, Béhin A, Bécane H, et al. Dilated cardiomyopathy in patients with mutations in anoctamin 5. Int J Cardiol 2013;168:76–9.

144. Rosales XQ, Moser SJ, Tran T, et al. Cardiovascular magnetic resonance of cardiomyopathy in limb girdle muscular dystrophy 2B and 2I. J Cardiovasc Magn Reson 2011;13:39.

145. Witting N, Duno M, Petri H, et al. Anoctamin 5 muscular dystrophy in Denmark: prevalence, genotypes, phenotypes, cardiac findings, and muscle protein expression. J Neurol 2013;260:2084–93.

146. Jenni R, Oechslin EN, van der Loo B. Isolated ventricular noncompaction of the myocardium in adults. Heart 2007;93:11–5.

147. Oechslin E, Jenni R. Left ventricular noncompaction revisited: a distinct phenotype with genetic heterogeneity? Eur Heart J 2011;32:1446–56.

148. Arbustini E, Favalli V, Narula N, et al. Left ventricular noncompaction: a distinct genetic cardiomyopathy? J Am Coll Cardiol 2016;68:949–66.

149. Zemrak F, Ahlman MA, Captur G, et al. The relationship of left ventricular trabeculation to ventricular function and structure over a 9.5-year follow-up: the MESA study. J Am Coll Cardiol 2014;64:1971–80.

150. Kimura K, Takenaka K, Ebihara A, et al. Prognostic impact of left ventricular noncompaction in patients with Duchenne/Becker muscular dystrophy—prospective multicenter cohort study. Int J Cardiol 2013;168:1900–4.

151. Roberts AE, Nixon C, Steward CG, et al. The Barth syndrome registry: distinguishing disease characteristics and growth data from a longitudinal study. Am J Med Genet A 2012;158:2726–32.

152. Ferreira C, Thompson R, Vernon H. Barth syndrome. In: Adam MP, Ardinger HH, Pagon RA, et al., editors. GeneReviews. Seattle: University of Washington, 1993-2018. Available at: http://www.ncbi.nlm.nih.gov/books/NBK247162/. Accessed April 11, 2018.

153. Sweeney RT, Davis GJ, Noonan JA. Cardiomyopathy of unknown etiology: Barth syndrome unrecognized. Congenit Heart Dis 2008;3:443–8.

154. Woiewodski L, Ezon D, Cooper J, et al. Barth syndrome with late-onset cardiomyopathy: a missed opportunity for diagnosis. J Pediat 2017; 183:196–8.

155. Mangat J, Lunnon-Wood T, Rees P, et al. Successful cardiac transplantation in Barth syndrome—single-centre experience of four patients. Pediatr Transplant 2007;11:327–31.

156. Kang SL, Forsey J, Dudley D, et al. Clinical characteristics and outcomes of cardiomyopathy in Barth syndrome: the UK Experience. Pediatr Cardiol 2016;37:167–76.

157. Reynolds S. Successful management of Barth syndrome: a systematic review highlighting the importance of a flexible and multidisciplinary approach. J Multidiscip Healthc 2015;8:345–58.

158. Rigaud C, Lebre AS, Touraine R, et al. Natural history of Barth syndrome: a national cohort study of 22 patients. Orphanet J Rare Dis 2013;8:70.

159. Labombarda F, Maurice M, Simon JP, et al. Cardiac abnormalities in type 1 facioscapulohumeral muscular dystrophy. J Clin Neuromuscul Dis 2017;18:199–206.

160. Hammans S. Myotonic dystrophy. Brain 2002;125:1225–6.

161. De Antonio M, Dogan C, Hamroun D, et al. Unravelling the myotonic dystrophy type 1 clinical spectrum: a systematic registry-based study with implications for disease classification. Rev Neurol 2016;172:572–80.

162. Sovari AA, Bodine CK, Farokhi F. Cardiovascular manifestations of myotonic dystrophy-1. Cardiol Rev 2007;15:191–4.

163. Christensen AH, Bundgaard H, Schwartz M, et al. Cardiac myotonic dystrophy mimicking arrhythmogenic right ventricular cardiomyopathy in a young sudden cardiac death victim. Circ Arrhythm Electrophysiol 2008;1:317–20.

164. Mathieu J, Allard P, Potvin L, et al. A 10-year study of mortality in a cohort of patients with myotonic dystrophy. Neurology 1999;52:1658.

165. Denicourt M, Pham MT, Mathieu J, Breton R. DM1 Patients with small CTG expansions are also at risk of severe conduction abnormalities. J Neuromuscul Dis 2015;2:99–105.

166. Meola G, Sansone V, Rotondo G, et al. PROMM in Italy: clinical and biomolecular findings. Acta Myol 1998;2:21–6.

167. Ricker K, Koch MC, Lehmann-Horn F, et al. Proximal myotonic myopathy: clinical features of a multisystem disorder similar to myotonic dystrophy. Arch Neurol 1995;52:25–31.

168. Day J, Ricker K, Jacobsen J, et al. Myotonic dystrophy type 2 molecular, diagnostic and clinical spectrum. Neurology 2003;60:657–64.

169. Meola G, Moxley RT. Myotonic dystrophy type 2 and related myotonic disorders. J Neurol 2004;251:1173–82.

170. Wahbi K, Meune C, Bécane HM, et al. Left ventricular dysfunction and cardiac arrhythmias are frequent in type 2 myotonic dystrophy: a case control study. Neuromuscul Disord 2009;19:468–72.

171. Lee TM, Maurer MS, Karbassi I, et al. Severe dilated cardiomyopathy in a patient with myotonic dystrophy type 2 and homozygous repeat expansion in ZNF9. Congest Heart Fail 2012;18: 183–6.

172. Schoser B, Ricker K, Schneider-Gold C, et al. Sudden cardiac death in myotonic dystrophy type 2. Neurology 2004;63:2402–4.

173. Groh WJ, Groh MR, Saha C, et al. Electrocardiographic abnormalities and sudden death in myotonic dystrophy type 1. N Engl J Med 2008; 358:2688–97.

174. Horga A, Rayan DLR, Matthews E, et al. Prevalence study of genetically defined skeletal muscle channelopathies in England. Neurology 2013;80:1472–5.

175. Matthews E, Fialho D, Tan S, et al. The non-dystrophic myotonias: molecular pathogenesis, diagnosis and treatment. Brain 2009;133:9–22.

176. Venance S, Cannon S, Fialho D, et al. The primary periodic paralyses: diagnosis, pathogenesis and treatment. Brain 2005;129:8–17.

177. Al-Ghamdi F, Darras BT, Ghosh PS. Spectrum of nondystrophic skeletal muscle channelopathies in children. Pediatr Neurol 2017;70:26–33.

178. Cannon SC. Skeletal muscle channelopathy: a new risk for sudden infant death syndrome. Lancet 2018. Available at: https://doi.org/10.1016/S0140-6736(18)30477-X. Accessed April 23, 2018.

179. Kostera-Pruszczyk A, Potulska-Chromik A, Pruszczyk P, et al. Andersen-Tawil syndrome: report of 3 novel mutations and high risk of symptomatic cardiac involvement. Muscle Nerve 2015;51:192–6.

180. Männikkö R, Wong L, Tester DJ, et al. Dysfunction of NaV1. 4, a skeletal muscle voltage-gated sodium channel, in sudden infant death syndrome: a case-control study. Lancet 2018;391: 1483–92.

181. Roman MJ, Devereux RB, Kramer-Fox R, O'Loughlin J. Two-dimensional echocardiographic aortic root dimensions in normal children and adults. Am J Cardiol 1989;64:507–12.

KEY WORDS arrhythmias, cardiomyopathies, dystrophy, myopathy, skeletal muscle

APPENDIX For an expanded Methods section as well as supplemental figures and tables, please see the online version of this paper.